Molecular Vision **1999; 5:13** <http://www.molvis.org/molvis/v5/p13>
Received 4 June 1999 | Accepted 22 July 1999 | Published 28 July 1999

Bilateral macular atrophy in blue cone monochromacy (BCM) with loss of the locus control region (LCR) and part of the red pigment gene

Radha Ayyagari, Laura E. Kakuk, Caraline L. Coats, Eve L. Bingham, Yumiko Toda, Joost Felius, Paul A. Sieving

Department of Ophthalmology and Visual Sciences, W. K. Kellogg Eye Center, University of Michigan, Ann Arbor, MI

Purpose: To describe unusual macular abnormalities in a family with blue cone monochromacy (BCM, or X-linked incomplete achromatopsia) and deletion of about 9.5 kb comprising part of the red pigment gene and the region upstream of the red pigment gene.
Methods: The molecular structure of the red and green pigment genes and the locus control region (LCR) upstream of the red gene were studied for deletions, rearrangements and point mutations by Southern blot analysis and PCR. Four affected males (ages 33, 45, 51, and 59) and a carrier female (age 58) were examined by funduscopy and fluorescein angiography. Extensive color vision testing as well as rod and cone electroretinography (ERG) were performed on two of them.
Results: Analysis showed that the 6 kb proximal red gene region, exon 1 and about 3.1 kb of intron 1 of the red gene are deleted in this family. Exons 2-6 of the red gene, all the exons of the green gene and the Tex 28 gene were present. Four affected males had bilateral macular changes, including three with overt atrophy. All had visual acuity of 20/200 and their color vision was typical for BCM, with the absence of long- and middle-wavelength sensitive cone function. The ERG showed normal rod responses, whereas the photopic cone and 30-Hz flicker responses were >95% reduced.
Conclusions: We report the unusual association between macular atrophy and BCM resulting from the loss of an approximately 9.5 kb region encompassing the LCR, proximal red gene promoter elements and exon 1 of the red gene. However, loss of the LCR and promoter is not sufficient to explain the phenotype since we have observed other BCM families with similar deletions who do not exhibit macular changes.

Blue cone monochromacy or BCM (OMIM 303700) is an ocular disorder characterized by the loss of normal color vision caused by the absence of long-wavelength (L, “red”) and medium-wavelength sensitive (M, “green”) cone function but with preservation of short-wavelength sensitive (S, “blue”) cone function [1]. Under photopic conditions, spectral sensitivity in BCM can be described by the short-wavelength sensitive cone (S-cone) fundamental alone [2], whereas in dimmer conditions an additional peak originating from the rods is observed [3].

In addition to abnormal color vision, BCM also affects other aspects of cone vision and typically causes reduced visual acuity, photophobia and congenital nystagmus. The photopic and flicker-electroretinogram (ERG) responses are severely reduced, indicating loss of cone signalling [4]. Although the condition results from alterations in the red and green color genes that are integral to cone photoreceptor function, BCM rarely causes atrophy of the cone rich macula but shows only subtle granularity of the retinal pigment epithelium (RPE) [4]. Here we present the phenotype and genotype of a BCM family with the rare condition of macular atrophy.

Individuals with normal color vision have one red gene and one or more green genes arranged in tandem on the “q” arm of chromosome X with a 600 bp locus control region (LCR) located upstream of the red gene [5,6]. The proximal red gene sequence between -1 and -445 bp was shown to be involved in controlling the expression of the red and green pigment genes [7,8]. The sequence between the red and green genes and 3' to the green gene also codes for the gene Tex 28 for which the function is unknown; the Tex 28 gene is transcribed in the direction opposite to the red and green genes [9]. BCM is associated with alterations in the red and green genes, including deletions, rearrangements and point mutations [10].

In the course of the clinical and molecular evaluation of 15 families with BCM at the University of Michigan, we found one BCM family with prominent bilateral macular atrophy. This unusual manifestation is rarely observed [10,11]. Here we present systematic clinical descriptions on four affected males and a carrier female in our family and describe the molecular analysis of the red and green color genes, and the 5' upstream region of the red gene [12].

METHODS

Clinical Analysis: Two affected brothers (IV-3, IV-4), their nephew (V-2), an affected male cousin (IV-13), and a female carrier (IV-5) in a five generation family with X-linked BCM (Figure 1) were available for examination. The two brothers and their nephew underwent extensive color vision testing, using the Ishihara plates, Berson’s BCM Plates [13] and the Farnsworth Dichotomous D-15 test, all performed under CIE Standard Illuminant C from a MacBeth Easel lamp. Two-de-

Correspondence to: Radha Ayyagari, PhD, Center for Retinal and Macular Degeneration, Department of Ophthalmology and Visual Sciences, W. K. Kellogg Eye Center, 1000 Wall Street, Ann Arbor, MI, 48105; Phone: (734) 647-6345; FAX: (734) 936-7231; email: ayyagari@umich.edu

gree Rayleigh matches were determined using a Nagel anomaloscope. BCM males typically fail the Ishihara test and make many random crossing errors on the D-15 test. Since S-cones do not contribute to the Rayleigh match, both BCM males and complete achromats generally match over the entire range of test intensities. However, the BCM Plates [13] present stimuli that are "equiluminant" for the rods but not for the S-cones; hence BCM males perceive contrast whereas complete achromats (rod monochromats) do not. Psychophysical dark-adapted rod absolute thresholds were evaluated using a Goldmann-Weekers dark-adaptometer and tested centrally and at six points in the visual field from 60° temporal to 20° nasal across the horizontal meridian. A standard clinical electroretinogram was recorded (details in Figure 2). Institutional review board approval for the study and informed consent from all participating individuals were obtained.

Southern blot analysis: DNA isolated from venous blood [14], and the structure of the red and green pigment genes, as well as the 12 kb region 5' upstream to the red gene transcription initiation site, and the Tex 28 gene (Figure 3A) were analyzed. Southern blot analysis of the red and green genes was performed using probes described by Nathans et al. [10]. Probes Br, Cr, Dr, Bg, Cg, and Dg detect possible gross structural changes in the red and green pigment genes (Figure 3B). The upstream region of the red gene was analyzed with probe Zr against Hind III digests of genomic DNA; probe Zr is an 800 bp fragment located 8.2 kb upstream from the red pigment gene transcription start site (Figure 3).

Amplification: Exons of the red and green pigment genes, the 5' upstream red gene region and the Tex 28 gene were amplified using primers designed for these sequences. Some of the primer sequences have been given elsewhere [15-20], and others we designed to analyze the red and green genes and the upstream region using Gene Bank sequences S44029, Z47066, Z68193, Z46936, M13300, M13301, M13304, M13305, K03491, K03492, U45954. Primers to analyze the exons of the Tex 28 gene(s) located at the 3' end of the red and green genes were derived from the 3' sequence of the red and green genes (Genbank Z46936, Z49258, Z68193). Primers used for analysis are given in Table 1. Most of the PCR reactions were carried out at 94 °C for 30 seconds, 55 °C for 30 seconds, and 72 °C for 40 seconds for 35 cycles. PCR products were analyzed on agarose or polyacrylamide gel to check for deletions.

The 12 kb sequence upstream to the red gene (Genbank Z68193, Z47066) was analyzed to detect the presence of known genes or ESTs using sequence analysis software (BLAST).

TABLE 1. PRIMERS

Primers used for the analysis of upstream red gene region, the red, green, and Tex 28 genes are listed according to their 5' to 3' positions on the chromosome. The "Location" column indicates the position of the primer 5' to 3' internal to the sequence of the accession number.

	Gene Specificity	Location	GenBank Accession	Sequence 5'-3'
1	upstream red	8127-8146	Z47066	CTTGAGACCAGGAGGCAGAG
2	upstream red	8444-8425	Z47066	TCCTGCTAGGCCACTTGTTT
3	upstream red	10696-10715	Z47066	CGTCAGAGTGGGGACAAGTT
4	upstream red	10887-10868	Z47066	TTTCCTGTCATTCAGGGACC
5	upstream red	10887-10868	Z47066	GGTCCCTGAATGACAGGAAA
6	upstream red	11366-11385	Z47066	AAACCAGAACCTGTGCCATC
7	upstream red	11737-11718	Z47066	GCTTTGTCTCAGTGCCTTCC
8	upstream red	11718-11737	Z47066	GGAAGGCACTGAGACAAAGC
9	upstream red	12151-12132	Z47066	AGTGAGCCATGATCCTCCAG
10	upstream red	12132-12151	Z47066	CTGGAGGATCATGGCTCACT
11	upstream red	12658-12639	Z47066	GAGCTAAACTCCAAGCAGGC
12	upstream red	12610-12629	Z47066	TGGCTCAAAGCCAAACAAAT
13	upstream red	12989-12965	Z47066	TTCCTGACCTCAGCTGATCC
14	upstream red	1-20	S44029	CGAATTCGGACCAGCCTAGC
15	upstream red	461-443	S44029	TCACAGATCCTGACTAATG
16	upstream red	443-461	S44029	CATTAGTCAGGATCTGTGA
17	upstream red	971-951	S44029	CAGAGATCCAGGAGGGCATCA
18	upstream red	951-971	S44029	TGATGCCCTCCTGGATCTCTG
19	upstream red	1481-1461	S44029	CAGCTCAGCCTCATAATCTCA
20	upstream red	1461-1481	S44029	TGAGATTATGAGGCTGAGCTG
21	upstream red	1964-1945	S44029	GCCATTTGCCTTTGACACTT
22	upstream red	1945-1964	S44029	AAGTGTCAAAGGCAAATGGC
23	upstream red	2373-2353	S44029	GGTCCCACACTCTTGCAGAAG
24	upstream red	2353-2373	S44029	CTTCTGCAAGAGTGTGGGAC
25	upstream red	3012-2995	S44029	ATCCAAGAATGTGAGACC
26	upstream red	2995-3012	S44029	GGTCTCACATTCTTGGAT
27	upstream red	3397-3380	S44029	CAAGTGCCTTTCTTCCTCT
28	upstream red	3380-3397	S44029	AGAGGAAGAAAGGCACTTG
29	upstream red	4297-4279	S44029	GACTTCTTAATGGGTACAG
30	upstream red	4279-4297	S44029	CTGTACCCATTAAGAAGTC
31	upstream red	4830-4811	S44029	GGCTACCCATAGCAAGAATG
32	upstream red	4811-4830	S44029	CATTCTTGCTATGGGTAGCC
33	upstream red	5430-5410	S44029	CGCACATCCTGCTGTTGGCTT
34	upstream red	5410-5430	S44029	AAGCCAACAGCAGGATGTGCG
35	upstream red	6018-6000	S44029	CATGGCTATGGAAAGCCCT
36	upstream red	5869-5889	S44029	GCCCAATTAAGAGATCAGGTA
37	red/green	608-588	M13300	CTGGCTCACGGAGTTGCTGTT
38	red/green	252-236	M13301	GCCAGAGACCTGGTTCACAAT
39	red/green	-	[20]	TTCCCCTTTGCTTTGGCTCAAAGC
40	red/green	-	[20]	TCCTGGGTCACCCCACCCTGCA
41	red	-	[19]	CATGATGATAGCGAGTGGGATG
42	red	-	[20]	CATCCCACTCGCTATCATCATG
43	red/green	-	[20]	TCCAACCCCCGACTCACTATC
44	red	121-141	M13304	GGTGGTGATGATCTTTGCGTA
45	red	-	[20]	GCAGTACGCAAAGATCATCACC
46	red	-	[18]	CATCAAAGGGTGGAAGGCGTAA
47	red/green	-	[19]	ACGGTATTTTGATGTGGATCTGCT
48	red/green	266-246	M13305	GCAGTGAAAGCCTCTGTGACT
49	red/green	1479-1499	U45954	ACAACTCCCTATGCCTGGGTC
50	red/green	-	[17]	TACTGGCCCCACGGCCTGAAG
51	red	-	[16]	GACGCAGTACGCAAAGATC
52	red/green	-	[16]	CTCTGTCGACTCATTTGAGGGCAGAGCAGC
53	red	83-100	M13302	GAGAGGTGGCTGGTGGTG
54	tex 28	20494-20513	Z68193	GAAAGGATCCTGGCAAAACA
55	tex 28	21188-21148	Z68193	CTTTCCCTGTTGCTGGAGAG
56	tex 28	6191-6210	Z46936	TTGGTTTGGGGGTATCAGAA
57	tex 28	6715-6696	Z46936	CGGAACTGAAGAGCACACAC
58	tex 28	22158-22177	Z46936	CCTTTCACCCTCCCATAGGT
59	tex 28	23011-23030	Z46936	AACGTGTCCAATTCTCCCAC
60	tex 28	26537-26556	Z46936	CCTGACCTCAAATGATTCCG
61	tex 28	27179-27160	Z46936	GGCCAGCACTTCATTGTCTT
62	tex 28	1392-1411	Z49258	CCCTTTAACCCAGCAGAACA
63	tex 28	1761-1742	Z49258	CGTGTGATTGTTGAGGAGGA

RESULTS

Clinical findings: Inheritance of disease in this family is consistent with an X-linked recessive pattern (Figure 1). Eleven living males and two deceased males in this family are known to be affected with poor acuity, color vision loss and photosensitivity. The family emigrated from England in the 1730s and mostly resides in the eastern part of Kentucky. Clinical findings on three affected males are summarized in Table 2.

IV-4 (age 51) had 20/200 bilateral visual acuity and small-amplitude jerk nystagmus. The anterior segments were normal, the lenses were clear, and the pupils did not show an afferent defect. The optic nerves had 0.2 physiologic cupping. The retinal vessel caliber was normal, and the peripheral retina showed no unusual pigmentation. Both maculae had a circular reddish lesion from circumscribed thinning of the RPE across the central one disc diameter (Figure 4). Goldmann visual fields were normal with the V4e target but were slightly constricted with the I4e target under standard background illumination (10 cd/m^2). The rod b-wave amplitude of the scotopic ERG was normal, whereas the photopic cone-driven b-wave and 30-Hz flicker responses were nearly absent (Figure 2). He identified none of the Ishihara plates (except the control plate) and made many random errors on

the D-15 test, but he repeatedly passed the BCM-Plate test, indicating "incomplete achromatopsia" with S-cones contributing to residual color discrimination. On Nagel anomaloscopy he made a Rayleigh match across the entire range of intensities of the test field, indicating no contribution of L- or M-cones in the macula.

His brother IV-3 (age 59) also reported life-long poor acuity, photoaversion, and inability to discriminate color. He had been examined at the University of Michigan at age 32 and was found to have visual acuity of 20/100 in each eye. Macular changes were observed on that examination and were described in the record as "pigmentary clumping with a 'beaten bronze' appearance". By age 59, he was pseudophakic with best-corrected visual acuities of 20/200 in both eyes. The center of both maculae showed extensive RPE atrophy and choriocapillary loss across a three disc-diameter region (Figure 4). The remainder of the fundus examination was unremarkable. At age 59, IV-3 failed the Ishihara and D-15 tests, and he consistently identified only one out of the four BCM Plates. On the Nagel anomaloscope, he was able to make a Rayleigh match across the entire intensity range of the test field although his performance was poor possibly due to the macular atrophy. Goldmann V4e visual fields were full, but I4e fields were moderately constricted. Psychophysical dark-adapted thresholds reached normal rod absolute levels. Scotopic ERG b-wave amplitude was normal, but the photopic b-wave was less than 3 µV, and no appreciable 30-Hz flicker response was present (Figure 2).

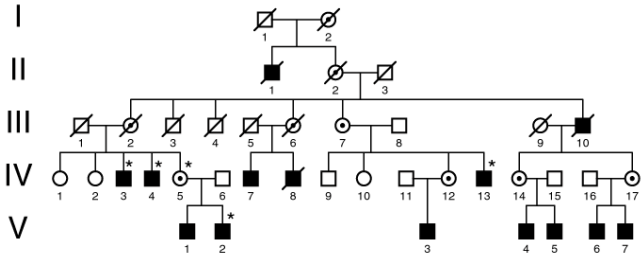

Figure 1. Pedigree of a family affected with X-linked BCM. A five generation pedigree of a family affected with X-linked BCM and reported herein. An asterisk (*) indicates the individuals that were available for clinical examination. The status of the others was determined using clinical history. Obligate carrier status was determined by the affected sons.

Their cousin, individual IV-13 (age 45), reported poor vision, photophobia and no color perception since childhood with further acuity deterioration as an adult. Both eyes gave 20/400 visual acuity at age 45. Anterior segments were normal and media were clear. He could not correctly identify any Ishihara color test plates, nor could he identify the colors of red, green, and blue objects. Although the peripheral retina was unremarkable, both macula showed RPE pigmentary and atrophic changes (Figure 4).

V-2 (age 33) had 20/200 visual acuity in both eyes. He had no ability to distinguish among the major color groups when presented with red, green, blue and yellow stimuli. The anterior segments of both eyes were normal and had no lens changes. The maculae showed marked RPE granularity across the central 1.2 disc diameter of both eyes and RPE thinning across the central 400 µm of the fovea in both eyes. This was unusual and outside the normal spectrum for a 33 year-old.

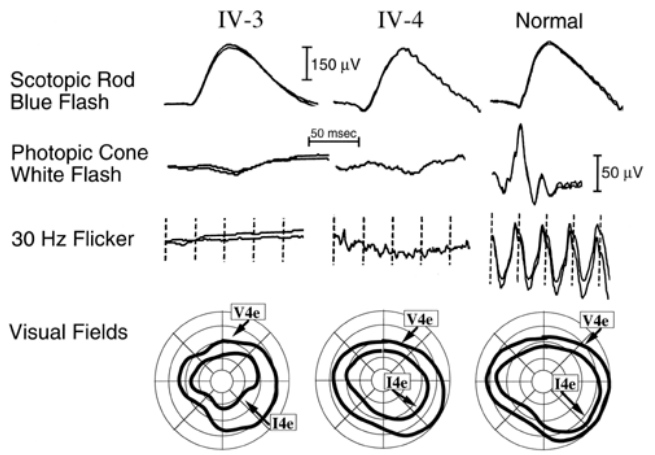

Figure 2. Visual function data. ERG and Goldmann visual fields on BCM affected brothers IV-3 and IV-4. Xenon-flash Ganzfeld ERGs used standard conditions [28] with fully dilated pupils and Burian-Allen bipolar corneal electrodes (Hansen Ophthalmic Instruments). Subjects were dark-adapted for 45 minutes before the scotopic rod ERG was elicited with -1.86 log cd-sec/m^2. Cone responses were isolated with 30 Hz flicker (4.2 cd-sec/m^2/flash) and by photopic adaptation of 3.3 log scotopic trolands and "white" flashes of 1.0 log cd-sec/m^2. Flicker tracings are computer averaged from 10 responses, others are single flash responses. Two responses for each test condition are shown for the normal and for IV-3; single tracings are shown for IV-4. The "Normal" responses are from an unaffected individual with amplitudes and wave forms conforming approximately to our population norms.

Table 2. Clinical Summary

Summary of clinical phenotype on three BCM affected males with overt macular atrophy. The following abbreviations were used in the table: "N/A" for "Not available," "NL" for "Normal," and "abnl" for "abnormal."

					Electroretinogram				
Individual/ Age at exam	Visual Acuity	Refraction	Visual Fields	Color Vision	Scotopic b-wave	Photopic b-wave	30 Hz Flicker	Dark Adapted Threshold	Fundus
IV-3 59 yr	20/200 20/200	pseudophakia	V4e full, I4e moderately constricted	0/15 Ishihara plates, D-15 many errors, BCM plates 1/4	290 µV (normal)	<3 µV (abnl)	<3 µV (abnl)	NL	Macular 3 dd areolar RPE atrophy OU with choriocapillary loss
IV-4 51 yr	20/200 20/200	-2.75 + 1.50 x 5 -2.00 + 1.75 x 4	V4e full, I4e slightly constricted	0/15 Ishihara plates, D-15 many errors, BCM plates 4/4	280 µV (normal)	<3 µV (abnl)	<3 µV (abnl)	NL	Macular 1 dd areolar RPE thinning & early atrophy
IV-13 45 yr	20/400 20/400	-7.37 + 1.75 x 110 -7.25 + 1.50 x 90	N/A Unable to identify	0/15 Ishihara plates,	N/A	N/A	N/A	N/A	Bilateral macular pigmentary atrophy

IV-5 (age 58) is a carrier of blue cone monochromacy who complained of difficulty with vision in dimly lit areas and experienced occasional sparkling photopsia. She never had ocular surgery and used no ocular medications. Visual acuity was 20/50 -2 in the right eye and 20/40 -3 in the left eye with myopic correction of -6.00 + 2.50 x 150° (right eye) and -6.50 + 2.50 x 45° (left eye). The anterior segments were quiet and both lenses were clear centrally but showed peripheral cortical spokes which did not interfere with vision to explain her decreased acuities. Color discrimination shows one significant crossing error on the Farnsworth D-15 test binocularly. On the Ishihara test, she identified only 2 of 14 plates plus the control plate, viewing with both eyes. Her fundi showed unusual discoloration of the fovea and had granular RPE of the central 1 disc diameter of the macula in both eyes. The foveal reflex was not readily appreciated. While this carrier female does not have overt macular atrophy, this is a very unusual macular appearance and is outside the normal spectrum for a 58 year-old (see discussion).

Analysis of the LCR and the upstream red gene region: The Nathans' Zr probe was used to screen the upstream region in individuals IV-3 and IV-4. This gave a novel band larger than the 7.2 kb expected if both H1 and H2 restriction sites are present (Figure 3). This indicates that a deletion or rearrangement in the upstream region had altered the fragment size of the Hind III restriction digestion product. We analyzed the 12 kb upstream red gene region further with 35 PCR primers (Table 1) used in different combinations that amplify the region in overlapping segments of 500 to 800 bp. Primers located 0 to 6.0 kb upstream from the initiating methionine of exon 1 of the red gene did not amplify any product, whereas the primers located 6.0 to 12.0 kb upstream gave the expected size products. These results indicate that the 5' boundary of the deletion extends no further than 6.0 kb (Figure 3C) and lies between 5.5 and 6.0 kb upstream.

Analysis of color genes and Tex 28: Southern blot analysis of the red and green gene regions gave the expected size fragments corresponding to Cr, Dr, Bg, Cg and Dg when hybridized with Nathans' probes (Figure 3B) [10]. The Br fragment corresponding to exon 1 and the 3.3 kb region at the 5' end of the intron 1 of the red gene was found to be missing. Further analysis was done with PCR primers that specifically amplify the exons of the red gene in segments ranging from approximately 200 bp to 8 kb (Table 1). The PCR analysis also did not result in the amplification of the exon 1 of the red gene confirming the deletion of exon 1 of the red gene. Absence of the fragment corresponding to Br and the presence of the expected size Cr fragment suggests that the 3' end of the deletion is located in intron 1 of the red gene between the 3' end of the exon 1 and the Bam H1 site located 3.4 kb downstream from the beginning of the intron 1.

No abnormality was noted in the amplified products of exons 2-6 of the red gene and any exons of the green and Tex 28 genes. Primers are available for the green gene but were

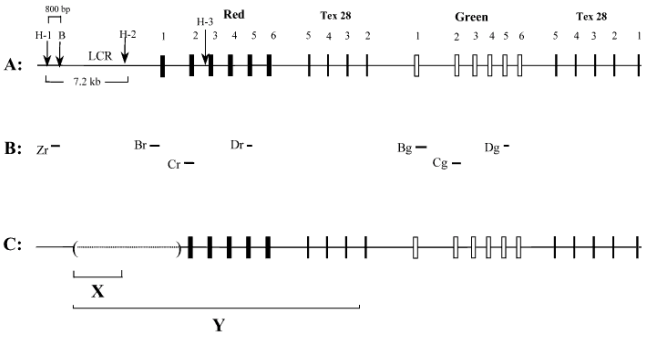

Figure 3. Organization and deletions of the red, green and Tex 28 genes, and probes for Southern blot analysis. **A**. Organization of the red, green and Tex 28 genes in normal individuals. Boxes indicate the position of exons and numbers above the boxes indicate the number of the exons. Hind III sites in the upstream red gene region and in intron 2 of the red gene are labeled as H-1, H-2, and H-3. "B" represents a Bam HI site. **B**. Position of the probes used for Southern blot analysis. Zr is a 800 bp probe corresponding to the sequence located between the Hind III and Bam HI sites in the upstream red gene region. Br and Bg hybridize to exon 1 of the red and green genes respectively. Cr and Cg correspond to exon 2 of the red and green genes and Dr and Dg represent exon 5 of the red and green genes respectively. **C**. Structure of the red, green and Tex 28 genes in this family with macular atrophy. Solid line indicates the region that is present. The dotted line in brackets indicates the deleted region. The position of the sequence shown in **C** corresponds to the structure of red, green and Tex 28 genes shown in **A**. X and Y represent the position of the deletion in families E:HS106 [10] and HS129 [11], respectively, that are reported to have maculopathy.

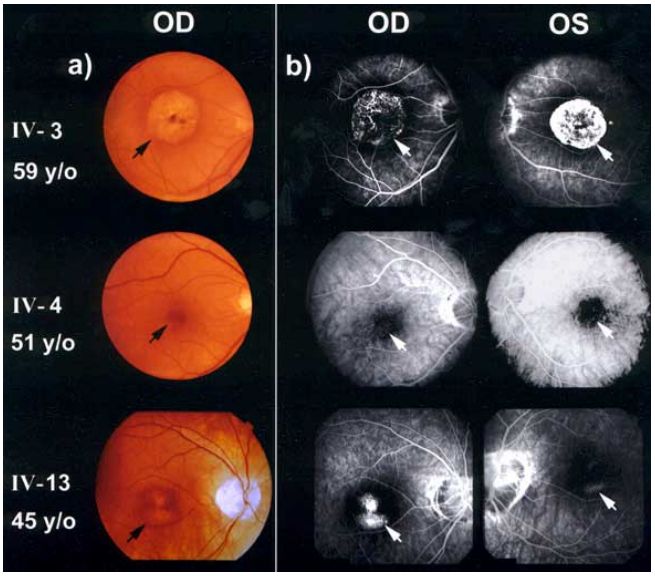

Figure 4. Clinical examination. Fundus photographs **A** and fluorescein angiograms **B** on affected males. Individual IV-3: Both maculae have extensive RPE atrophy and choriocapillary loss across the central three disc diameters that is readily apparant in the color photograph and the angiograms (early phase right eye and late phase left eye). Individual IV-4: Both maculae show circumscribed thinning of the RPE across the central one disc diameter that gives a reddish hue in the color photograph and a subtle RPE "window defect" on the angiograms. Individual IV-13: Bilateral macular atrophy is evident.

not used because the multiple copies would mask any deletion in a single green gene. Five primer pairs were used to amplify exons of the Tex 28 gene in segments of approximately 350 to 950 bp, and the appropriate size bands were obtained. The exons of Tex 28 are identically duplicated in the multiple copies that are interspersed between the red and green genes, and this analysis can not distinguish between them. However, all results of the Southern and PCR analyses were consistent with the expectation that exon 1 and part of intron 1 of the red gene are missing and the remaining exons of the red gene, and all exons of the green gene and the Tex 28 gene are present (Figure 3C).

Blast analysis of the 12 kb sequence of the proximal red gene region did not identify the presence of any other known coding sequences indicating the absence of any other known genes in the deleted region. The boundaries of the deletion were determined to a resolution of few hundred base pairs and the deletion observed in this family was found to co-segregate with the disease phenotype in this family.

DISCUSSION

Bilateral progressive macular atrophy is an unusual manifestation of BCM. In this family, the atrophy is distinct from aging maculopathy, since individual IV-3 exhibited atrophy by the young age of 32, individual IV-13 shows this at age 45, and IV-4 has circumscribed RPE thinning by age 51 (Figure 4). In addition, the affected male V-2 (age 33) shows early macular degeneration, with RPE granular pigment and thinning in both eyes (Figure 4). His mother, the carrier female IV-5 has macular changes outside the normal spectrum for her age. We have observed a female BCM carrier in a different family who also has pigmentary maculopathy (data not shown), and we believe this is due to their carrier state in both cases. The remainder of the individuals in this family were unavailable for our examination. From the individuals available, the maculopathy cosegregates with BCM through five meioses. This family alone does not make the case for causation, but this report stands in the context of two other such family reports [10,11] and indicates that macular involvement can occur in conjunction with BCM.

Fleischman and O'Donnell [11] reported one BCM family with macular atrophy and noted slight worsening of visual acuity and color vision during a twelve year follow-up period, as well as the development of pigmentary changes in the fovea. There is one additional report of a male affected with BCM and a ten year history of progressive bilateral central retinal degeneration [10]. In our family, individual IV-3 showed progressive atrophy between the ages 32 and 59. The overall incidence of macular atrophy in older BCM males is uncertain, since these individuals typically are ascertained in childhood.

Molecular analysis of all three BCM families diagnosed so far with macular atrophy (our family presented here, E:HS106 [10] and HS129 [11]) showed the presence of large deletions in the upstream red gene region encompassing the 600 bp locus control region, which is located about 3.5 kb upstream of the red gene (Figure 3C). The LCR and the proximal red gene sequence between -1 and -445 were shown to be involved in the regulation of red and green gene expression [6-8]. BCM family (E:HS106) of Nathans et al. [10] has a 2.5 kb deletion upstream of the red gene that includes the LCR, and family (HS129) of Fleischman and O'Donnell [11] has a 41 kb deletion that includes the LCR, regulatory elements and part of the red pigment gene [15] (Figure 3C). In our family, the deletion includes the LCR, proximal red gene regulatory elements, exon 1 of the red gene and a portion of intron 1 (Figure 3C). Though the size of the deletions in these three families are different, all of them show loss of the LCR.

Loss of the LCR will result in the loss of expression [6,7] of the red and green opsins. These cone visual pigments are the major transmembrane proteins present in the cone photoreceptor outer segments [21]. An analogous loss of rhodopsin expression occurs in the rhodopsin knockout mouse, and this results in the lack of formation of rod photoreceptor outer segments and leads to degeneration of the rods and subsequently the cones over a three month period [22]. In males affected with BCM, one can speculate that the fovea may never have cone outer segments, and that the cone nuclei ultimately may be expected to die. Given the dynamic interplay between photoreceptors and the RPE, it is surprising that macular atrophy is not found more frequently in patients with BCM, since the cones are the predominant photoreceptor in the central macula.

Loss of the LCR should cause major loss of red and green opsin expression, and it is not surprising that this results in poor visual acuity. The relationship to the macular atrophy is however, less clear, since we have studied several other BCM families who also have deletions of the entire LCR, but do not show macular degeneration [23]. Similarly, Nathans et al. [15] described five different BCM families with deletions in the LCR and did not report macular atrophy. Thus, the deletion of the LCR apparently does not always cause macular degeneration in BCM families.

Since the macula is cone-rich, one would expect abnormalities of genes that are structurally or functionally important for cones would be associated with macular degeneration. However, this is reported infrequently thus far, and a number of cases result from rod-specific genes. The ATP-binding cassette transporter (ABCR) gene involved in Stargardt's macular degeneration is expressed in rods rather than cones [24]. The cone-rod homeobox gene (CRX) causes both cone and rod disease; however, patients with CRX mutations have parafoveal vision loss that initially spares visual acuity [25]. If macular degeneration is caused by a single gene defect that affects primarily cone photoreceptors, then we might expect central visual function including visual acuity to be affected first, since cones vastly outnumber rods within the fovea [26,27]. The present report describes a BCM family in which macular degeneration is associated with the color genes that affect cone photoreceptor function.

ACKNOWLEDGEMENTS

FFB Molecular Genetics Grant (Ayyagari) and FFB Center Grant, both from The Foundation Fighting Blindness, Hunt Valley, MD; R01 EY06094; NEI Vision Core Grant EY07003 and M01 RR00042. The authors thank Dr. Jeremy Nathans for providing his BCM probes, Dr. Atanacio Tiongson for some

of the clinical information on IV-13, and Bradley Nelson for preparation of the ocular fundus photographs.

REFERENCES

1. Blackwell HR, Blackwell OM. Blue mono-cone monochromacy: a new color vision defect. J Optical Soc America 1957; 47:338-41.
2. Alpern M, Lee GB, Spivey BE. Pi_1 cone monochromatism. Arch Ophthalmol 1965; 74:334-7.
3. Blackwell HR, Blackwell OM. Rod and cone receptor mechanisms in typical and atypical congenital achromatopsia. Vision Res 1961; 1:62-107.
4. Krill AE. Hereditary retinal and choroidal diseases. Hagerstown (MD): Harper & Row; 1972.
5. Vollrath D, Nathans J, Davis RW. Tandem array of human visual pigment genes at Xq28. Science 1988; 240:1669-72.
6. Wang Y, Macke JP, Merbs SL, Zack DJ, Klaunberg B, Bennett J, Gearhart J, Nathans J. A locus control region adjacent to the human red and green visual pigment genes. Neuron 1992; 9:429-40.
7. Shaaban SA, Deeb SS. Functional analysis of the promoters of the human red and green visual pigment genes. Invest Ophthalmol Vis Sci 1998; 39:885-96.
8. Li Q, Timmers AM, Yan W, Chiodo VA, Hauswirth WW. In vivo determination of cone promoter requirements using a human red opsin promoter in a recombinant AAV. Invest Ophthalmol Vis Sci 1999; 40:S761.
9. Hanna MC, Platts JT, Kirkness EF. Identification of a gene within the tandem array of red and green color pigment genes. Genomics 1997; 43:384-6.
10. Nathans J, Davenport CM, Maumenee IH, Lewis RA, Hejtmancik JF, Litt M, Lovrien E, Weleber R, Bachynski B, Zwas F, et al. Molecular genetics of human blue cone monochromacy. Science 1989; 245:831-8.
11. Fleischman JA, O'Donnell FE Jr. Congenital X-linked incomplete achromatopsia. Evidence for slow progression, carrier fundus findings, and possible genetic linkage with glucose-6-phosphate dehydrogenase locus. Arch Ophthalmol 1981; 99:468-72.
12. Nathans J, Merbs SL, Sung CH, Weitz CJ, Wang Y. Molecular genetics of human visual pigments. Annu Rev Genet 1992; 26:403-24.
13. Berson EL, Sandberg MA, Rosner B, Sullivan PL. Color plates to help identify patients with blue cone monochromatism. Am J Ophthalmol 1983; 95:741-7. pubmed6602551
14. Bell GI, Karam JH, Rutter WJ. Polymorphic DNA region adjacent to the 5' end of the human insulin gene. Proc Natl Acad Sci U S A 1981; 78:5759-63.
15. Nathans J, Maumenee IH, Zrenner E, Sadowski B, Sharpe LT, Lewis RA, Hansen E, Rosenberg T, Schwartz M, Heckenlively JR, et al. Genetic heterogeneity among blue-cone monochromats. Am J Hum Genet 1993; 53:987-1000.
16. Deeb SS, Lindsey DT, Hibiya Y, Sanocki E, Winderickx J, Teller DY, Motulsky AG. Genotype-phenotype relationships in human red/green color-vision defects: molecular and psychophysical studies. Am J Hum Genet 1992; 51:687-700.
17. Winderickx J, Sanocki E, Lindsey DT, Teller DY, Motulsky AG, Deeb SS. Defective colour vision associated with a missense mutation in the human green visual pigment gene. Nat Genet 1992; 1:251-6.
18. Reyniers E, Van Thienen MN, Meire F, De Boulle K, Devries K, Kestelijn P, Willems PJ. Gene conversion between red and defective green opsin gene in blue cone monochromacy. Genomics 1995; 29:323-8.
19. Neitz J, Neitz M, Kainz PM. Visual pigment gene structure and the severity of color vision defects. Science 1996; 274:801-4.
20. Neitz M, Neitz J, Jacobs GH. Genetic basis of photopigment variations in human dichromats. Vision Res 1995; 35:2095-103.
21. Nathans J, Thomas D, Hogness DS. Molecular genetics of human color vision: the genes encoding blue, green, and red pigments. Science 1986; 232:193-202.
22. Humphries MM, Rancourt D, Farrar GJ, Kenna P, Hazel M, Bush RA, Sieving PA, Sheils DM, McNally N, Creighton P, Erven A, Boros A, Gulya K, Capecchi MR, Humphries P. Retinopathy induced in mice by targeted disruption of the rhodopsin gene. Nat Genet 1997; 15:216-9.
23. Ayyagari R, Bingham EL, Toda Y, Sieving PA. Blue cone monochromacy: molecular rearrangements and genotype-phenotype correlations. Invest Ophthalmol Vis Sci 1997; 38:S679.
24. Allikmets R, Singh N, Sun H, Shroyer NF, Hutchinson A, Chidambaram A, Gerrard B, Baird L, Stauffer D, Peiffer A, Rattner A, Smallwood P, Li Y, Anderson KL, Lewis RA, Nathans J, Leppert M, Dean M, Lupski JR. A photoreceptor cell-specific ATP-binding transporter gene (ABCR) is mutated in recessive Stargardt macular dystrophy [published erratum appears in Nat Genet 1997; 17:122]. Nat Genet 1997; 15:236-46.
25. Swain PK, Chen S, Wang QL, Affatigato LM, Coats CL, Brady KD, Fishman GA, Jacobson SG, Swaroop A, Stone E, Sieving PA, Zack DJ. Mutations in the cone-rod homeobox gnene are associated with the cone-rod dystrophy photoreceptor degeneration. Neuron 1997; 19:1329-36.
26. Osterberg GA. Topography of the layer of rods and cones in the human retina. Acta Ophthalmol 1935; 6:1-102.
27. Curcio CA, Sloan KR, Kalina RE, Hendrickson AE. Human photoreceptor topography. J Comp Neurol 1990; 292:497-523.
28. Standard for clinical electroretinography. International Standardization Committee. Arch Ophthalmol 1989; 107:816-9.