

# Therapeutic effects of a novel venom abstract (ZK002) solution in an alkali-burned corneal wound-healing model

Wen-yan Peng,<sup>1</sup> Fei Wang,<sup>2</sup> Shuang-jian Yang,<sup>3</sup> Qin-yan Sun,<sup>3</sup> Heng-shen Zhou,<sup>3</sup> Xiaoyi Li,<sup>3</sup> Zheng-xuan Jiang,<sup>2</sup> Shi-you Zhou<sup>1</sup>

(The first two authors contributed equally to this work.)

<sup>1</sup>State Key Laboratory of Ophthalmology, Zhongshan Ophthalmic Center, Sun Yat-sen University, Guangdong Provincial Key Laboratory of Ophthalmology and Visual Science, Guangdong Provincial Clinical Research Center for Ocular Diseases, Guangzhou, China; <sup>2</sup>The second hospital of Anhui medical university, Hefei, China; <sup>3</sup>Zhaoke (Guangzhou) Ophthalmology Pharmaceutical Limited, Guangzhou, China

**Purpose:** Corneal alkali burns can progress to corneal epithelial defects, inflammation, scarring, and angiogenesis, potentially leading to blindness. Therefore, we examined the therapeutic effects of a novel ophthalmic solution (ZK002) on wound healing in alkali-burned rat corneas.

**Methods:** In this study, we attempted to treat alkali-exposed rat corneas using topical application of either an ophthalmic solution with ZK002 or an anti-vascular endothelial growth factor agent for 14 days. We evaluated corneal edema, corneal neovascularization area, and histological changes. We also assessed the inflammatory (MMP-9, MMP-2, and interleukin-1 $\beta$ ) and angiogenic (vascular endothelial growth factor receptor 2, VEGFR2) markers. Levels of inflammatory (matrix metalloproteinase (MMP)-9, MMP-2, and interleukin-1 $\beta$ ), profibrotic ( $\alpha$ -smooth muscle actin,  $\alpha$ -SMA; transforming growth factor- $\beta$ 2, TGF- $\beta$ 2), and angiogenic (vascular endothelial growth factor-receptor 2, VEGFR2) factors, as well as peroxisome proliferator-activated receptor  $\gamma$  (PPAR $\gamma$ ) mRNA expression, were measured.

**Results:** The analyses showed that alkali exposure caused an increase in corneal edema and fibrosis with corneal neovascularization. The accumulation of  $\alpha$ -smooth muscle actin-positive myofibroblasts and the deposition of transforming growth factor- $\beta$ 2 on the alkali-exposed corneas were noted on day 14. The mRNA expression levels of interleukin-1 $\beta$ , MMP-9, MMP-2, VEGFR2, and profibrotic factors were decreased in the ZK002 group compared with the control group during the early period of corneal alkali burns on day 14. However, the expression level of PPAR $\gamma$  mRNA was increased in the ZK002 group.

**Conclusions:** ZK002 decreased the fibrotic reaction and prevented neovascularization in the cornea after an alkali burn. Therefore, the novel ophthalmic solution ZK002 could be a potentially promising therapeutic clinical treatment for corneal wound healing.

Avascular transparency is a characteristic of corneal “angiogenic privilege. Corneal neovascularization (CorNV) is an important event in the proliferative phase of corneal wound healing and is a leading cause of vision loss and a high-risk factor in transplant rejection. secondary to severe ocular trauma (such as a corneal alkali burn) [1,2]. Human corneal alkali burns may be caused accidentally at the workplace, laboratory, or home, or intentionally as a result of an assault, especially in lower socioeconomic groups [1,2]. Human corneal alkali burns are commonly caused by alkalis, such as sodium hydroxide, ammonia, and calcium

oxide, which cause more damage than acids because of their rapid penetration through the cornea and anterior chamber. Damage is relative to the pH; the higher the pH, the greater the damage to the eye, with the most significant injury occurring around pH 11–11.5. Alkali chemicals are responsible for 60% of ocular burns [3,4]. These progress to corneal epithelial defects, scarring, and angiogenesis, which can reduce corneal transparency and potentially lead to blindness [5,6].

It is essential to stabilize the ocular surface in the acute phase of corneal alkali burns to promote corneal wound healing and prevent visual threats, such as corneal scarring and CorNV formation. Supportive medical management, surgical options such as amniotic membrane transplantation (AMT) [7,8], tenonplasty [9,10], and tenonplasty combined with AMT [11], and therapeutic strategies, including topical antibiotics, steroids, non-steroidal anti-inflammatory drugs, and autologous serum, are inadequate in controlling inflammation in the acute stage [12]. Moreover, anti-vascular

---

Correspondence to: Shi-you Zhou, State Key Laboratory of Ophthalmology, Zhongshan Ophthalmic Center, Sun Yat-sen University, Guangdong Provincial Key Laboratory of Ophthalmology and Visual Science, Guangdong Provincial Clinical Research Center for Ocular Diseases, Guangzhou 510060, China; Phone: 8620-6661-5460, FAX:8620-87333271, email: zhoushiy@mail.sysu.edu.cn

endothelial growth factor (VEGF) agents are available for the management of corneal alkali burns [13]. However, the treatment of corneal alkali burns is challenging and a major concern for clinicians. There is a need to develop effective therapeutic strategies that can promote corneal wound healing, restore the initial stage, and improve prognosis at a later reconstruction period to preserve vision.

Corneal alkali burns are characterized by the expression of proangiogenic factors [14]. The balance between proangiogenic and antiangiogenic molecules is essential for corneal avascularity and optical clarity [15,16], and excessive proangiogenic molecules can lead to corneal keratolysis [17]. Thus, strategies for treating acute ocular alkali burns aim to reduce proangiogenic molecules and accelerate wound healing and restoration to prevent complications [18].

ZK002, a type of angiostatin with a molecular weight range of 25,000–35,000 daltons was isolated from the serum of *Agkistrodon acutus* venom. *Agkistrodon* has many biologic and pharmacological properties and is the only economically important species in the subfamily Viperidae, which is widely distributed in China. ZK002 is a distinct type of snake venom known for its antiangiogenic activity by attenuating the activation of pro-inflammatory genes in vitro (patent CN113185595A; patent CN102372770A). Despite these potential beneficial effects, topical administration of ZK002 to angiogenic reactions on the ocular surface and its effects on profibrotic factors have not been investigated. Therefore, this study focused on assessing the therapeutic effects of ZK002 in an alkali-burned corneal wound-healing model.

## METHODS

**Animals:** Female Sprague Dawley (SD) rats (age: 2–3 months; weight: 180–220 g; n = 120) were purchased from Southern Medical University (Guangzhou, Guangdong, China) for animal experiments. Experimental and animal management procedures were performed in accordance with the Association for Research in Vision and Ophthalmology Statement on the Use of Animals in Ophthalmic and Vision Research and the Guidelines of the Animal Care Committee of the Zhongshan Ophthalmic Center at Sun Yat-sen University (approval ID: 2019–136, Guangzhou, China). The rats were maintained in a standard pathogen-free environment ( $24 \pm 2^\circ\text{C}$ ,  $50 \pm 5\%$  humidity) with a 12-h light/dark cycle. Prior to treatment, all SD rats were confirmed to be free from ocular diseases after a one-week adaptation period. The right eye of each SD rat was selected for the experiment.

**Alkali-induced corneal injury model and treatment:** CorNV was induced by alkali-burn injury in rats using a previously described method, with slight modifications [19]. Briefly, the

SD rats were anesthetized with an intraperitoneal injection of 10% chloral hydrate at a dose of 0.35 ml/100 g of body weight and topically anesthetized with a drop of 0.5% proparacaine hydrochloride (Alcaine eye drops, Alcon Inc., Fort Worth, TX). A circular piece of Whatman #3 filter paper (3 mm in diameter) soaked with 5- $\mu\text{l}$  1 M NaOH for 10 s was placed on the central cornea of the right eye for 30 s, and the injured eyes were immediately rinsed with 45 ml 0.9% saline solution for 45 s.

After the alkali-burn injury, the SD rats were randomly divided into three groups (n = 30, each) as follows: (1) ZK002 group, (2) anti-VEGF group, and (3) control group. A fourth group of normal SD rats (n = 30, no alkali-burn injury) were used as naïve controls. Each group was treated three times daily using eye drops or ointments for 14 consecutive days. The rats in the ZK002 and anti-VEGF groups received topical administration of ZK002 (1.5 mg/ml, Zhaoke [Guangzhou] Ophthalmology Pharmaceutical Limited, Guangzhou, China) or an anti-VEGF agent (1.5 mg/ml, KH902 [Conbercept]; Chengdu Kanghong Biotech Co., Ltd., Sichuan, China), respectively. The rats received 10  $\mu\text{l}$  of the drop each time, using a pipette, immediately after the alkali-burn injury, followed by a 0.3% tobramycin ophthalmic ointment (Tobrex, Alcon Inc.). The SD rats in the control group received a topical administration of 0.3% tobramycin ophthalmic ointment, while the normal SD rats were used as naïve controls.

**Biomicroscopic examination:** The eyes were examined and photographed with a digital camera (Cannon, Tokyo, Japan) attached to a slit-lamp microscope (SL-120; Zeiss Inc., Jena, Germany) on days 0, 1, 2, 7, 10, and 14 after alkali-burn injury. The degree of CorNV and corneal epithelium defects were visualized using fluorescence staining of the ocular surface using 0.5% fluorescein sodium salt (Sigma-Aldrich, St. Louis, MO), and the corneas were examined under cobalt blue light. Three photos with satisfactory full-face imaging were used for the image analysis. The length of the corneal neovessels was measured using ImageJ software (ImageJ 1.46. Java 1.6.0–20 [32-bit]; Wayne Rasband, National Institutes of Health [NIH], Bethesda, MD), which was downloaded from the US NIH website and used for quantitative analysis, as described in a previous report [20]. Assessments were performed by blinded observers who had no prior knowledge of the procedures. The area of CorNV was measured, and the percentage of corneal involvement was calculated.

To measure the severity of CorNV, the rats were anesthetized and examined under a slit lamp on days 1, 2, 7, 10, and 14 after the alkali-burn injury. All observations were recorded by a single experienced ophthalmologist who was

blinded to the allocation of rats to each group. The CorNV area was calculated using the following formula:

$$S = C/12 - \pi \times (r^2 - [r - L]^2),$$

where  $S$  is the area,  $C$  is time,  $L$  is the radius of the border of the vessel, and  $r$  is the radius of the cornea [21]. An image analyzer (Image Pro Plus 6.0; Media Cybernetics, Rockville, MD) was used to measure the radius.

**Histopathological and immunohistochemical analyses:** At 0 h, 6 h, 48 h, and 14 days post-alkaline burn, three rats were randomly chosen from each of the study groups, general anesthesia was administered, and whole eyeballs were harvested for histopathological and immunohistochemical examinations. Subsequently, the SD rats were sacrificed. The eyeballs were fixed in FAS eyeball fixative solution (G1109; Servicebio, Wuhan, China), routinely processed, and embedded in paraffin.

Hematoxylin and eosin (H&E) staining was performed according to standard techniques. Corneal thickness was measured using ImageJ software. The proportion and extent of CorNV were determined as described previously [22]. Sections were taken from the central region of the cornea, and CorNV was evaluated in at least three sections from each eye.

Immunohistochemical staining was performed to detect protein expression. Briefly, corneal tissue sections were incubated overnight at 4°C with primary antibody (VEGF receptor 2 [VEGFR2], 1:1500, Invitrogen, gz1234;  $\alpha$ -smooth muscle actin [ $\alpha$ -SMA], 19,245, Cell Signaling Technology, Danvers, MA). The cells were then incubated with a secondary antibody (1:500) at room temperature for 1 h. The immune complexes were detected using a DAB Substrate Kit (G1212, Servicebio Technology Co., Ltd., Wuhan, China) according to the manufacturer's instructions. The tissues were counterstained with hematoxylin and mounted. An inverted

fluorescent microscope was used for histological observations and image capture. Micrographs of the peripheral region of the cornea (three fields per side at  $\times 200$  magnification) were taken to measure the mean staining intensity of these markers. Images were analyzed using ImageJ.

**Analysis of mRNA expression:** At day 14, all SD rats received general anesthesia; their corneas were harvested and flash frozen in liquid nitrogen at the time of surgery and stored at  $-80^\circ\text{C}$  until used for RNA extraction. Subsequently, the SD rats were sacrificed.

Total RNA was isolated from the corneal tissue using TRIzol™ reagent (Invitrogen, Boston, MA). One microgram of DNase I-treated RNA (Roche Applied Science, Mannheim, Germany) was reverse transcribed using the SuperScript® II Reverse Transcriptase system (Life Technologies Corp., Carlsbad, CA). Quantification of mRNA was performed using a quantitative polymerase chain reaction (qPCR) with SYBR Green. The sequences of the PCR primers are listed in Table 1.

The cycling protocol was as follows: denaturation ( $95^\circ\text{C}$  for 10 min), 45 cycles of amplification ( $95^\circ\text{C}$  for 15 s,  $59^\circ\text{C}$  for 15 s, and  $72^\circ\text{C}$  for 20 s), and a final extension at  $72^\circ\text{C}$ . A melting curve analysis was also performed to ascertain the specificity of the amplified product. The expression of each gene was normalized to that of glyceraldehyde-3-phosphate dehydrogenase. Expression was quantified as fold change using the  $\Delta\Delta\text{Ct}$  method.

**Statistical analyses:** All data are expressed as means  $\pm$  standard errors. Differences between multiple groups were compared by one-way ANOVA (ANOVA) using GraphPad Prism (Prism 5 for Windows, version 5.01, 1992–2007; GraphPad Software, Inc., San Diego, CA). Individual comparisons were obtained by ANOVA (Dunnett's multiple

TABLE 1. PRIMER SEQUENCE OF qRT-PCR.

Gene	Forward	Reverse
VEGFR2	TGGCAATTCCCCTCAAGC	CCTTGGTCACTCTTGGTCACTG
MMP-9	CTCCTGGTGCTCCTGGCTCTAG	GCTGTGTGTCCTGAGGTTGG
MMP-2	GTGACGGCTTCTCTGGTGTTT	CAGGGCTGTCCATCTCCATTGC
IL-1 $\beta$	CTCACAGCAGCATCTCGACAAGAG	TCCACGGGCAAGACATAGGTAGC
PPAR $\gamma$	CCATCGAGGACATCCAAGACAACC	GTGCTCTGTGACAATCTGCCTGAG
$\alpha$ -SMA	CTCTTTGTCTCCACCAACTACT	TGTAGTGGGAGTACTCATGGTA
TGF- $\beta$ 2	ATTGCTGCCTTCGCCCTCTTAC	TGGTGTGTTGTGTGTCTGAACTCC
GAPDH	ACGGCAAGTTCAACGGCACAG	CGACATACTCAGACCAGCATCAC

Abbreviations: qRT-PCR, quantitative real-time polymerase chain reaction; VEGFR2, vascular endothelial growth factor receptor 2; IL-1 $\beta$ , interleukin 1 $\beta$ ; PPAR $\gamma$ , peroxisome proliferator-activated receptor  $\gamma$ ; MMP, matrix metalloproteinase;  $\alpha$ -SMA,  $\alpha$ -smooth muscle actin; TGF- $\beta$ 2, transforming growth factor- $\beta$ 2; GAPDH, glyceraldehyde-3-phosphate dehydrogenase.

comparison test). Differences were considered statistically significant at  $p < 0.05$ .

## RESULTS

*Topical administration of ZK002 promotes antiangiogenic effects on alkali-burn-induced corneal neovascularization:* To examine the role of ZK002 in the modulation of wound healing in alkali-burned corneas, we first evaluated CorNV by comparing the neovascularization length of the ZK002-treated group and the other groups at different time points. In the control group, newly formed limbal vessels sprouted into the central corneas on day 7 and reached the central corneas on day 10. Although new blood vessels of similar lengths were present in the eyes 14 days after injury, the area taken up by new blood vessels was higher on day 14 than on day 10. However, in the rats in the ZK002-treated group, the length of the new blood vessels was significantly lower than that in the control or anti-VEGF-treated groups (Figure 1A). The areas of CorNV in each group were measured, and their percentages for the entire cornea were calculated, as shown in Figure 1B.

After the corneal alkali burn, the corneal epithelium and basement membrane were disrupted. The central corneal epithelium was found to be defective based on fluorescein staining (FL+), and the corneal stroma showed edema (Figure 1A) immediately after the alkali burn. Disrupted corneal epithelium must undergo rapid re-epithelialization to maintain tissue homeostasis and avoid further infection and damage to the underlying stroma [23]. Therefore, we examined the regeneration of the corneal epithelium using fluorescein staining, which can easily identify corneal epithelial defects. The results showed that topical application of ZK002 did not delay corneal epithelium regeneration after injury.

To further elucidate the effects of ZK002 on corneal wound healing, histopathological analysis of the degree of neovascularization was performed after H&E staining. On day 14 after injury, newly formed blood vessels were prominent in the anterior part of the corneal stroma in the control and anti-VEGF groups. This pathological change was significantly decreased in the ZK002 group (Figure 2A). Further, corneal thickness (Figure 2B-first upper panel) and corneal stromal thickness (Figure 2B-second upper panel) were significantly lower in the ZK002 group than in the anti-VEGF and control groups. These results indicated that ZK002 could reduce CorNV and corneal stromal thickness in alkali-burn injured SD rats as compared with the control or anti-VEGF groups.

*ZK002 treatment reduces proangiogenic gene and protein expression in the corneas of Sprague-Dawley rats after*

*alkali burn:* We further examined several growth factors and molecules related to angiogenesis in alkali-burned corneal tissues to clearly demonstrate the effects of ZK002 on corneal wound healing. To confirm the antiangiogenic effects of ZK002, real-time (RT)-qPCR and immunohistochemistry were performed to examine the changes in the expression of angiogenic factors, such as VEGFR2 (Figure 3A), matrix metalloproteinase (MMP)-9 (Figure 3B), and MMP-2 (Figure 3C), in alkali-burned corneas. On day 14, the ZK002-treated alkali-burned corneas exhibited a significant decrease in the intracorneal mRNA expression of these three angiogenic genes (Figure 3). The protein levels of MMP-9 (Figure 3D) and VEGFR2 (Figure 3E) also decreased, whereas the MMP-2 level remained normal. These results demonstrate that the anti-VEGF effect of ZK002 was superior to that of the anti-VEGF agent.

*ZK002 exerts effects on peroxisome proliferator-activated receptor  $\gamma$  and pro-inflammatory factor expression in alkali-burned corneas:* Peroxisome proliferator-activated receptor  $\gamma$  (PPAR $\gamma$ ) is hypothesized to have anti-inflammatory, anti-neovascularization, and antifibrotic effects. RT-qPCR was performed to investigate the mRNA expression levels of PPAR $\gamma$  at day 14 in the ZK002, anti-VEGF, and control groups. PPAR $\gamma$  mRNA expression was markedly upregulated in the ZK002 group compared with that in the control group ( $p < 0.01$ ; Figure 4A). However, the protein expression of PPAR $\gamma$  was normal on day 14. Additionally, inflammatory genes such as IL-1 $\beta$  was markedly downregulated by ZK002 treatment (Figure 4B), which is consistent with the immunohistochemistry results (Figure 4C).

*ZK002-treated corneas exhibit antifibrotic effects:* Since fibrosis/scar formation of the corneal stroma is a hallmark of injured corneal tissue, we confirmed the levels of fibrosis-related genes in the cornea after alkali-burn injury. Similar to the expression pattern of angiogenic genes, fibrogenic genes, including  $\alpha$ -SMA and transforming growth factor- $\beta$ 2 (TGF- $\beta$ 2), were markedly downregulated in the ZK002-treated alkali-burned corneas compared with anti-VEGF-treated and untreated alkali-burned corneas. RT-qPCR and immunohistochemistry were performed to evaluate the fibrotic changes on day 14 after alkali injury. Interestingly, the proportions of  $\alpha$ -SMA and TGF- $\beta$ 2 in the corneal regions were significantly lower in the ZK002 group than in the control groups (Figure 5). Treatment with ZK002 ( $p < 0.01$ ) and anti-VEGF ( $p < 0.05$ ) resulted in lower mRNA expression of TGF- $\beta$ 2 compared with the control group (Figure 5A). However, ZK002 ( $p < 0.05$ ) treatment resulted in lower mRNA expression of  $\alpha$ -SMA compared with the control group (Figure 5B).

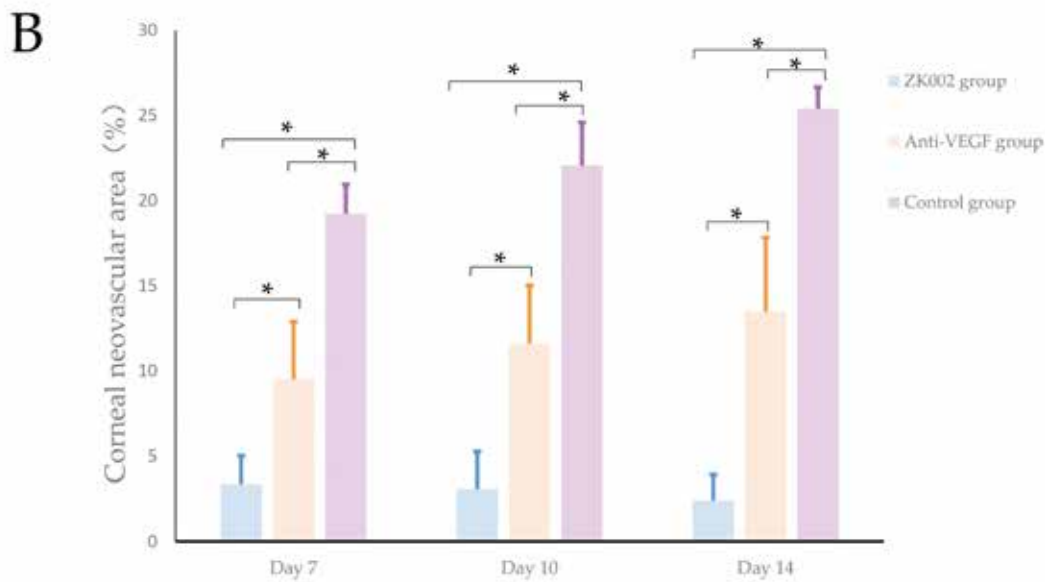
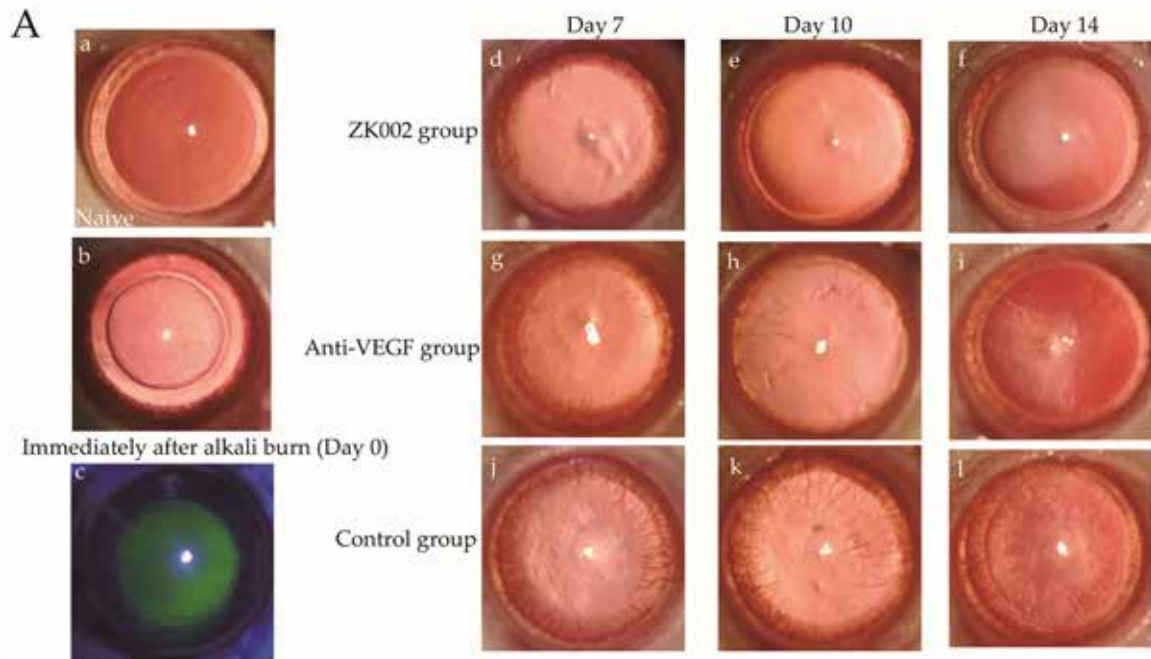


Figure 1. Antiangiogenic effect of ZK002 on alkali burn induced corneal neovascularization. **A**: Representative slit-lamp stereomicroscopic appearance of SD rat eyes on days 7, 10, and 14 with or without ZK002 or anti-vascular endothelial growth factor treatment. Panels **B** and **C** present images immediately after the alkali burn (**C**: corneal fluorescein staining), and Panel **A** presents the normal cornea. **B**: The percentage of corneal neovascular area (CorNV, %) was determined (n=7 per group) in the three groups on days 7, 10, and 14. Values are expressed as the mean  $\pm$  standard error of the mean. Data were analyzed using ANOVA. A value of  $p < 0.05$ , was considered statistically significant.

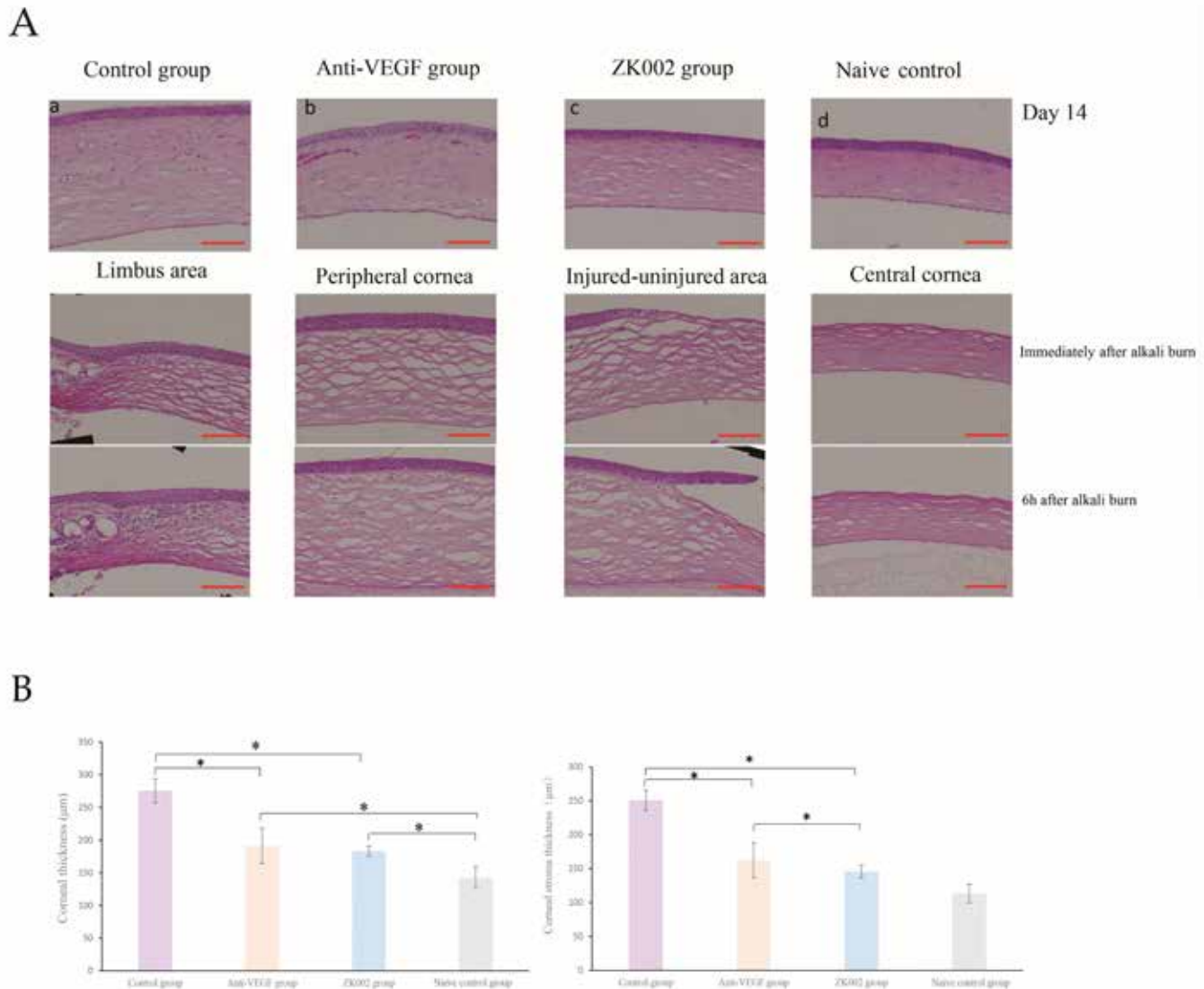


Figure 2. Histopathological findings of ZK002 in alkali-burned corneas. **A:** Representative hematoxylin and eosin-stained corneal sections are shown. Bar, 100 µm. **B:** Corneal thickness and corneal stromal thickness were analyzed from corneas obtained from ZK002-treated, anti-VEGF treated, or untreated SD rats 14 days after an alkali burn. Data were expressed as the mean ± SD. Data were analyzed using analysis of variance. A value of  $p < 0.05$  was considered statistically significant ( $*p < 0.01$ ).

## DISCUSSION

In this study, we evaluated the effects of ZK002 using an acute corneal injury model of corneal alkali burns, which is a well-characterized rat model of corneal inflammation, neovascularization, and fibrosis-related wound healing. We found that topical administration of ZK002 at a concentration of 1.5 mg/ml three times a day effectively inhibited CorNV, inflammation, and fibrosis in this SD rat alkali-burn model. Previous studies have demonstrated that ZK002 plays a pivotal role in blocking the phosphorylation of key molecules

(VEGFR2, eNOS, p38, LIMK, Hsp27, and Erk1/2) of the VEGF-induced signaling cascade in human umbilical vein endothelial cells (HUVECs). Further, the expression levels of pro-inflammatory cytokines, such as interleukin (IL)-6, IL-1 $\beta$ , tumor necrosis factor- $\alpha$ , and IL-8 mRNA, decreased when HUVECs were pretreated with ZK002 for 24 h, with lipopolysaccharide as an inflammation inducer and angiogenesis factors ([patent CN113185595A](#); [patent CN102372770A](#)). In accordance with these in vitro results, our study data show that ZK002 prevents neovascularization induced by

alkali injury in SD rat corneal tissues. The expression of angiogenesis-related genes, such as VEGFR2, MMP-9, and MMP-2, decreased in injured corneas following treatment with ZK002.

Corneal epithelial defects at the site of injury and subsequent regeneration in this area are important pathophysiological responses in the alkali-induced corneal injury model. In this study, we found that the ZK002-treated group had no effect on corneal re-epithelialization on day 6 after corneal alkali burn. Compared with the normal corneal epithelial cells, the ZK002-treated group significantly inhibited the

migration of human corneal epithelial cells in the low serum condition, although it had little effect in full serum medium conditions in vitro, considering that ZK002 had no side effect on the corneal epithelium capacity for regeneration in the normal group.

CorNV formation is a complicated pathological process that consists of two phases: (1) excessive increase in angiogenic growth factors, which are dependent on the proliferation of the vascular endothelium, and (2) the remodeling of extracellular matrix components and the activation of cytokines [24]. To further explore the mechanisms of

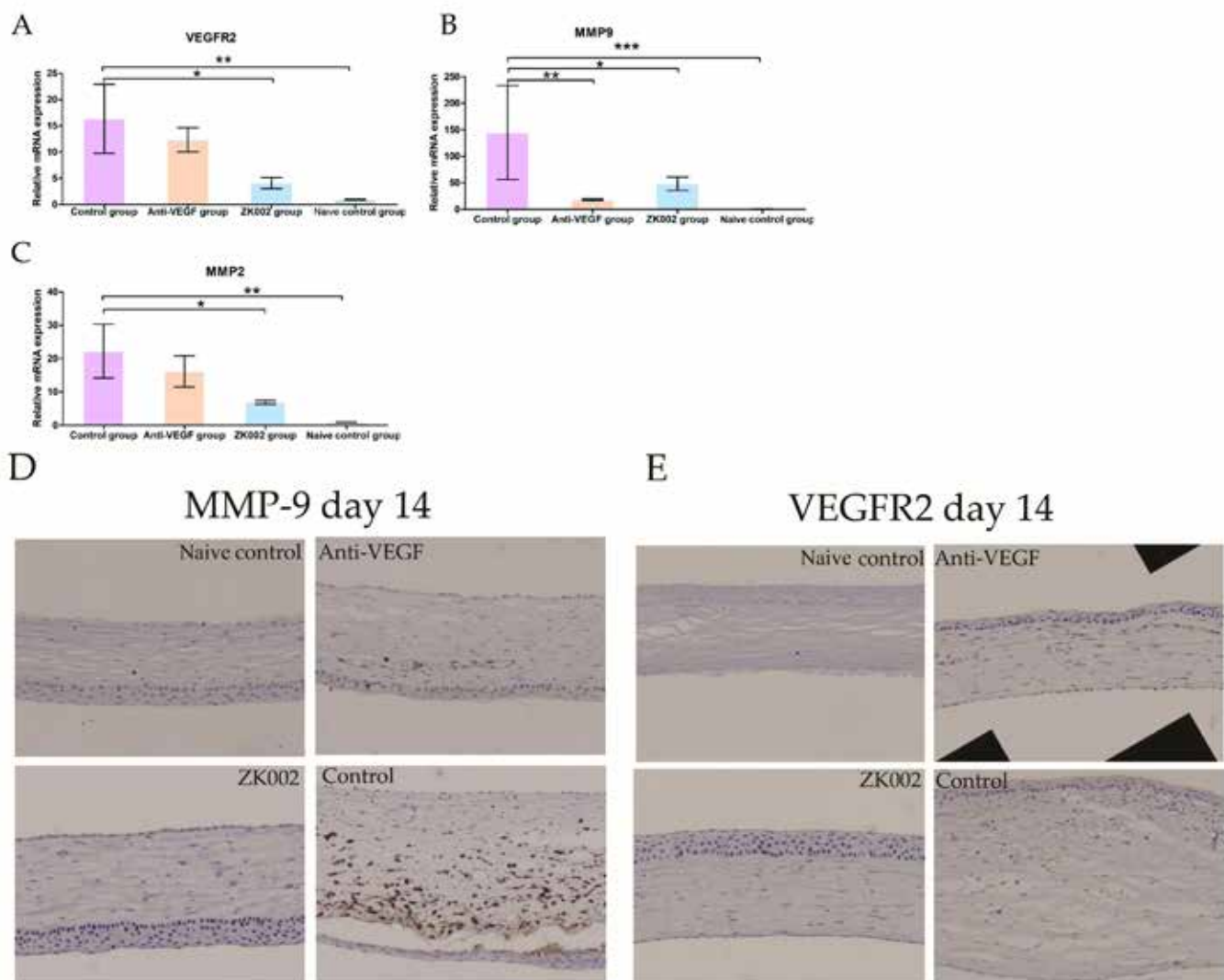


Figure 3. ZK002 reduced proangiogenic factors expression in SD rats after corneal alkali burn. RT qPCR was used to detect the mRNA levels of proangiogenic factors VEGFR2 (A), MMP-9 (B), and MMP-2 (C) in alkali-burned corneas. Data were expressed as the mean ± SD. Data were analyzed using analysis of variance and Dunnett’s multiple comparison test. Compared all groups vs. Each group. A value of  $p < 0.05$  was considered statistically significant. \* $p < 0.05$ , \*\* $p < 0.01$ , \*\*\* $p < 0.0001$ . Representative immunohistochemistry of MMP-9 (D) and VEGFR2 (E) on day 14 in corneal sections are shown. Bar = 100  $\mu$ m.

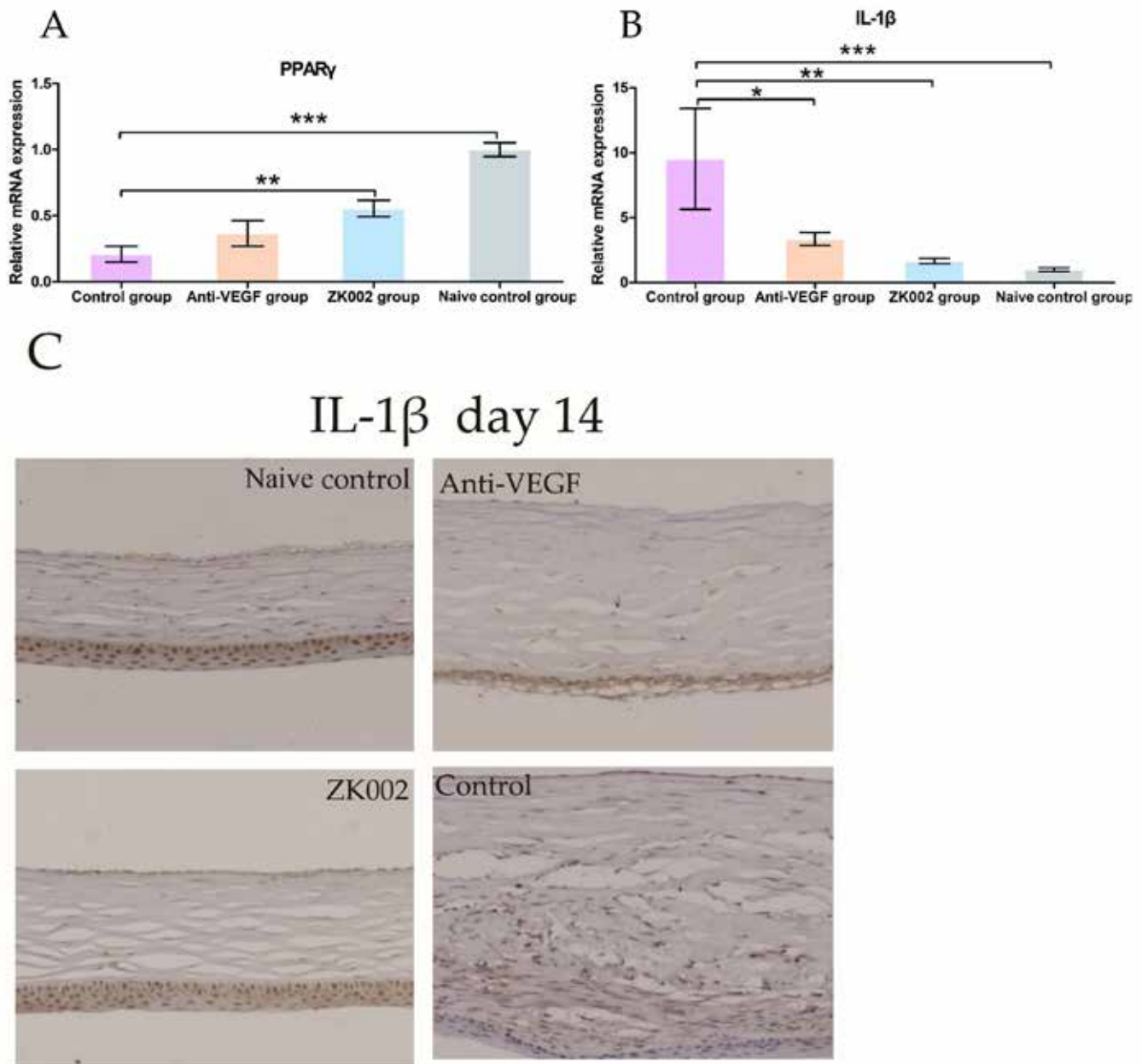


Figure 4. ZK002 reduced PPAR  $\gamma$  and pro-inflammatory factor expression in the alkali burned cornea. RT-qPCR was used to detect the mRNA levels of PPAR $\gamma$  (A) and IL-1 $\beta$  (B) in alkali-burned corneas. Data were expressed as the mean  $\pm$  SD. Data were analyzed using analysis of variance and Dunnett's multiple comparison test. Compared all groups vs. each group. A value of  $p < 0.05$  was considered statistically significant. \* $p < 0.05$ , \*\* $p < 0.01$ , \*\*\* $p < 0.0001$ . Representative immunohistochemistry of IL-1 $\beta$  on day 14 in corneal sections of all groups are shown (C). Bar=100  $\mu$ m.

ZK002 in this study, we examined the expression of some major angiogenesis-related cytokines, including angiogenic factors, inflammatory cytokines, and MMPs. In this study, ZK002 downregulated the mRNA and protein expression of VEGFR2. VEGFR2 has been demonstrated to be the predominant mediator of VEGF-stimulated endothelial cell

migration, proliferation, survival, and enhanced vascular permeability [25].

Alkali burn-induced CorNV is closely related to inflammation. After chemical burns, inflammatory cells are recruited to the injured area and release inflammatory



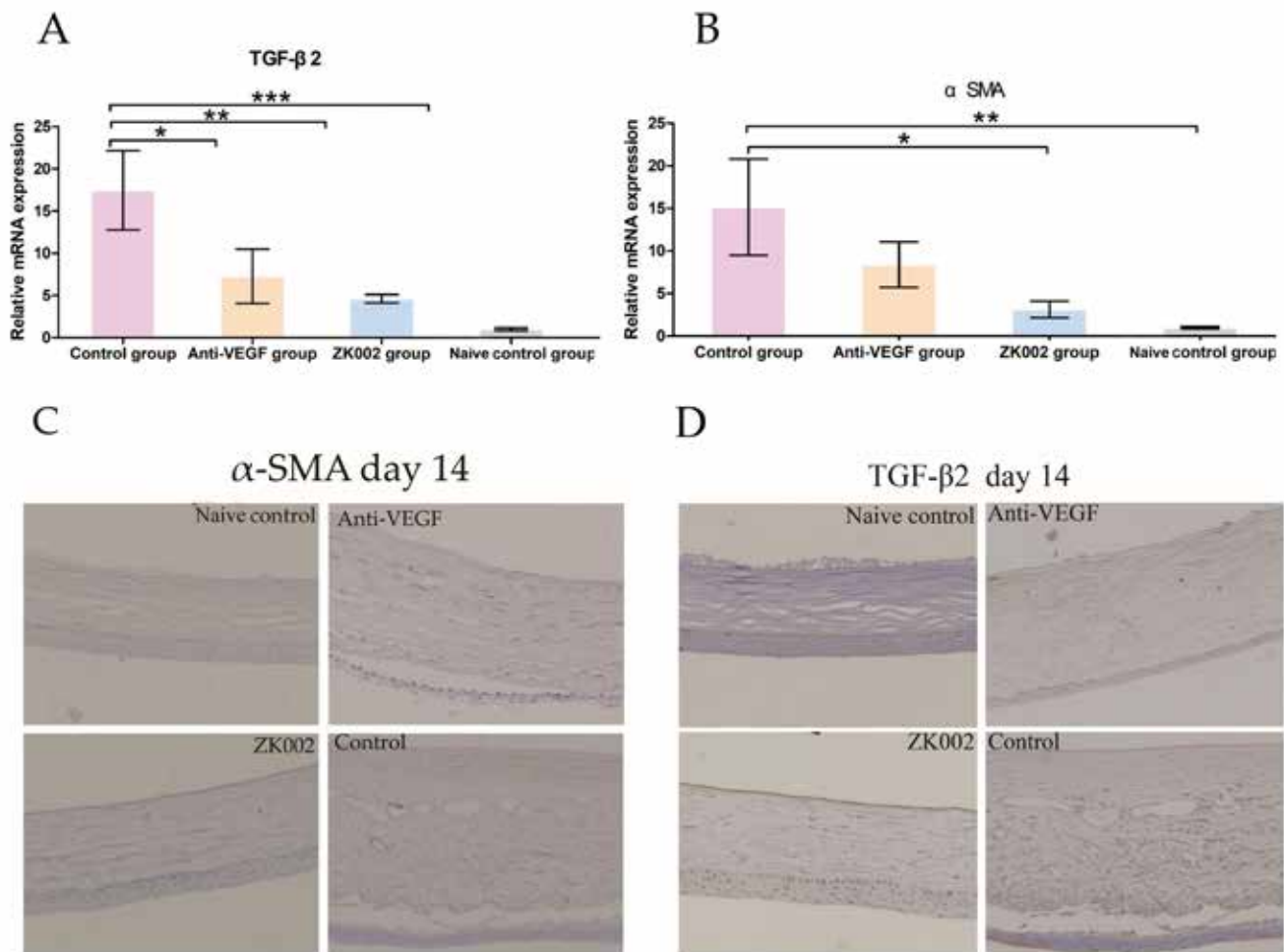


Figure 5. ZK002 reduced fibrogenic factor expression in the alkali burned cornea. RT-qPCR showed marked suppression in the mRNA expressions of TGF-β2 (A) and α-SMA (B) in the burned cornea after ZK002 treatment compared with the control group on day 14. Data were expressed as the mean ± SD. Data were analyzed using analysis of variance and Dunnett's multiple comparison test. Compared all groups vs. each group. A value of  $p < 0.05$  was considered statistically significant. \* $p < 0.05$ , \*\* $p < 0.01$ , \*\*\* $p < 0.0001$ . Representative immunohistochemistry of TGF-β2 (C) and α-SMA (D) on day 14 in corneal sections of all groups are shown. Bar=100 μm.

cytokines and MMPs; then, they induce the formation of CorNV and retard corneal epithelial recovery [3,26]. IL-1 is an important proinflammatory cytokine in the induction of CorNV [27]. Some studies have shown that reducing the production of IL-1 could inhibit CorNV [28-30]. Our results show that the expressions of IL-1β mRNA and protein in the ZK002 group were significantly lower than those in the control group. This may be due to the ZK002-induced inhibition of the production and activity of MMP-2 and MMP-9, as shown in this study. Previous studies have demonstrated that MMP-2 and MMP-9 can activate the IL-1β precursor into mature IL-1β during inflammation [31]. Furthermore, in this study, we observed the enhancement of corneal wound

healing after ZK002 treatment. The above findings show that ZK002 effectively inhibited angiogenesis by suppressing the inflammatory reaction and promoting corneal wound healing.

MMPs, a family of zinc-dependent extracellular endoproteases, are one of the primary angiogenic factors involved in CorNV. They have been demonstrated to be essential factors in the formation and development of CorNV by degrading components of the extracellular matrix and facilitating the migration of vascular endothelial cells to the lesion [32]. MMP-2 and MMP-9, known as gelatin A and gelatin B, respectively, play crucial roles in angiogenesis [33-35]. In our study, the mRNA and protein levels of MMP-2 and MMP-9 were significantly reduced after ZK002 treatment. This may

partly contribute to the antiangiogenic function of ZK002 on CorNV exerted by inhibiting remodeling of the burned corneal stroma.

Since a chemical corneal burn induces severe tissue fibrosis, resulting in scar formation that causes opacification of the stroma and vision loss, it is important to inhibit fibrotic tissue changes when treating alkali-burned corneas. Keratocyte proliferation and transdifferentiation of keratocytes into myofibroblasts, which are distinguished from keratocytes by the expression of  $\alpha$ -SMA, are necessary for fibrotic wound repair in injured corneal tissue, and TGF- $\beta$ 2 is a major mediator of these responses [36]. Thus, inhibition of the action of TGF- $\beta$  with a neutralizing antibody can promote the corneal wound-healing response by inhibiting keratocyte proliferation and myofibroblast differentiation [37]. Our study showed that the mRNA expression of fibrosis-related genes, such as  $\alpha$ -SMA and TGF- $\beta$ 2, was significantly reduced in the ZK002-treated group. This should be further investigated to verify the effects of ZK002 on the TGF- $\beta$ 2 signaling pathway associated with keratocyte proliferation and myofibroblast formation.

In this study, the expression of PPAR $\gamma$  mRNA was higher, whereas its protein expression remained unchanged in the ZK002 group compared with the other alkali-burned groups, which may be because PPAR $\gamma$  protein returned to normal at day 14. This study mainly examined the effects of an ophthalmic solution of ZK002 on the wound healing of corneas injured by alkali burns. One limitation of this study is that alkali burns and subsequent healing in the injured corneas were evaluated only 14 days after ZK002 treatment.

For alkali-burned corneas, we recommend preparing ZK002 as an eye drop for topical administration to avoid exposing the human body to its possible toxicity due to a high dose. In the future, we need to determine the concentration of ZK002 required in the cornea to effectively inhibit CorNV, as well as design appropriate delivery modes, such as eye drops or ointment, for the topical application of ZK002 to injured eyes.

In summary, our study indicates that topical administration of ZK002 accelerated wound healing in corneal injury induced by an alkali burn. The mechanism of this wound healing involves the inhibition of VEGFR2, MMP-9, MMP-2, and IL-1 $\beta$  production and the promotion of PPAR $\gamma$  activation. In addition, reduced CorNV and fibrosis were observed in injured corneas following ZK002 treatment. Thus, ZK002 may be of therapeutic benefit in the treatment of corneal diseases involving angiogenesis and fibrosis.

## ACKNOWLEDGMENTS

Co-corresponding authors: S.Y.Z. (zhoushiy@mail.sysu.edu.cn) and Z.X.J. (jiangzhengxuan@ahmu.edu.cn) Funding: This study was partially supported by Guangzhou Municipal Science and Technology Planning Project (Grant number 202201020502) and Natural Science Foundation of Guangdong Province, China (Grant Number 2022A1515011140). The sponsors or funding organizations had no role in the design and implementation of this research. Data Availability Statement: Not applicable. Conflicts of Interest: The authors declare no conflict of interest.

## REFERENCES

1. Azar DT. Corneal angiogenic privilege: angiogenic and anti-angiogenic factors in corneal avascularity, vasculogenesis, and wound healing (an American Ophthalmological Society Thesis). *Trans Am Ophthalmol Soc* 2006; 104:264–302.
2. Epstein RJ, Stulting RD, Hendricks RL, Harris DM. Corneal neovascularization. Pathogenesis and inhibition. *Cornea* 1987; 6:250-7. [PMID: 2446823].
3. Wagoner MD. Chemical injuries of the eye: current concepts in pathophysiology and therapy. *Surv Ophthalmol* 1997; 41:275-313. [PMID: 9104767].
4. Reim M, Redbrake C, Schrage N. Chemical and thermal injuries of the eyes. Surgical and medical treatment based on clinical and pathophysiological findings. *Arch Soc Esp Ophthalmol* 2001; 76:79-124. [PMID: 11228610].
5. Pfister RR. The effects of chemical injury on the ocular surface. *Ophthalmology* 1983; 90:601-9. [PMID: 6888853].
6. Okada Y, Reinach PS, Shirai K, Kitano A, Kao WW, Flanders KC, Miyajima M, Liu H, Zhang J, Saika S. TRPV1 involvement in inflammatory tissue fibrosis in mice. *Am J Pathol* 2011; 178:2654-64. [PMID: 21641388].
7. Joseph A, Dua HS, King AJ. Failure of amniotic membrane transplantation in the treatment of acute ocular burns. *Br J Ophthalmol* 2001; 85:1065-9. [PMID: 11520758].
8. Burcu A, Yalniz-Akkaya Z, Ozdemir MF, Erdem E, Onat MM, Ornek F. Surgical rehabilitation following ocular chemical injury. *Cutan Ocul Toxicol* 2014; 33:42-8. [PMID: 23713679].
9. Kenyon KR. Decision-making in the therapy of external eye disease: noninfected corneal ulcers. *Ophthalmology* 1982; 89:44-51. [PMID: 6280121].
10. Kuckelkorn R, Schrage N, Reim M. Treatment of severe eye burns by tenonplasty. *Lancet* 1995; 345:657-8. [PMID: 7898215].
11. Peng WY, He LW, Zeng P, Chen DC, Zhou SY. Tenonplasty combined with amniotic membrane transplantation for patients with severe ocular burns induced anterior segment necrosis. *J Burn Care Res* 2020; 41:668-73. [PMID: 32006003].

12. Sharma N, Kaur M, Agarwal T, Sangwan VS, Vajpayee RB. Treatment of acute ocular chemical burns. *Surv Ophthalmol* 2018; 63:214-35. [PMID: 28935121].
13. Lai PX, Chen CW, Wei SC, Lin TY, Jian HJ, Lai IP, Mao JY, Hsu PH, Lin HJ, Tzou WS, Chen SY, Harroun SG, Lai JY, Huang CC. Ultrastrong trapping of VEGF by graphene oxide: anti-angiogenesis application. *Biomaterials* 2016; 109:12-22. [PMID: 27639528].
14. Bakunowicz-Łazarczyk A, Urban B. Assessment of therapeutic options for reducing alkali burn-induced corneal neovascularization and inflammation. *Adv Med Sci* 2016; 61:101-12. [PMID: 26651127].
15. Lu P, Li L, Liu G, van Rooijen N, Mukaida N, Zhang X. Opposite roles of CCR2 and CX3CR1 macrophages in alkali-induced corneal neovascularization. *Cornea* 2009; 28:562-9. [PMID: 19421039].
16. Qazi Y, Maddula S, Ambati BK. Mediators of ocular angiogenesis. *J Genet* 2009; 88:495-515. [PMID: 20090210].
17. Wang L, Huang Y, Du G, Dong Y, Guo H, Wang D, Yu J, Wang Q, Chen B, Hou L. Long-term outcomes and complications of Moscow Eye microsurgery Complex in Russia (MICOF) keratoprosthesis following ocular surface burns: clinical experience in China. *Br J Ophthalmol* 2015; 99:1669-74. [PMID: 26034080].
18. Ljubimov AV, Saghizadeh M. Progress in corneal wound healing. *Prog Retin Eye Res* 2015; 49:17-45. [PMID: 26197361].
19. Zhou SY, Xie ZL, Xiao O, Yang XR, Heng BC, Sato Y. Inhibition of mouse alkali burn induced-corneal neovascularization by recombinant adenovirus encoding human vasohibin-1. *Mol Vis* 2010; 16:1389-98. [PMID: 20680097].
20. Proia AD, Chandler DB, Haynes WL, Smith CF, Suvarnamani C, Erkel FH, Klintworth GK. Quantitation of corneal neovascularization using computerized image analysis. *Lab Invest* 1988; 58:473-9. [PMID: 2451768].
21. D'Amato RJ, Loughnan MS, Flynn E, Folkman J. Thalidomide is an inhibitor of angiogenesis. *Proc Natl Acad Sci USA* 1994; 91:4082-5. [PMID: 7513432].
22. Lu P, Li L, Liu G, Zhang X, Mukaida N. Enhanced experimental corneal neovascularization along with aberrant angiogenic factor expression in the absence of IL-1 receptor antagonist. *Invest Ophthalmol Vis Sci* 2009; 50:4761-8. [PMID: 19458323].
23. Chen M, Matsuda H, Wang L, Watanabe T, Kimura MT, Igarashi J, Wang X, Sakimoto T, Fukuda N, Sawa M, Nagase H. Pretranscriptional regulation of TGFβ1 by PI polyamide prevents scarring and accelerates wound healing of the cornea after exposure to alkali. *Mol Ther* 2010; 18:519-27. [PMID: 19920805].
24. Grossniklaus HE, Kang SJ, Berglin L. Animal models of choroidal and retinal neovascularization. *Prog Retin Eye Res* 2010; 29:500-19. [PMID: 20488255].
25. Roskoski R Jr. VEGF receptor protein-tyrosine kinases: structure and regulation. *Biochem Biophys Res Commun* 2008; 375:287-91. [PMID: 18680722].
26. Carter RT, Kambampati R, Murphy CJ, Bentley E. Expression of matrix metalloproteinase 2 and 9 in experimentally wounded canine corneas and spontaneous chronic corneal epithelial defects. *Cornea* 2007; 26:1213-9. [PMID: 18043179].
27. Imanishi J, Kamiyama K, Iguchi I, Kita M, Sotozono C, Kinoshita S. Growth factors: importance in wound healing and maintenance of transparency of the cornea. *Prog Retin Eye Res* 2000; 19:113-29. [PMID: 10614683].
28. Dana MR, Zhu SN, Yamada J. Topical modulation of interleukin-1 activity in corneal neovascularization. *Cornea* 1998; 17:403-9. [PMID: 9676913].
29. Stapleton WM, Chaurasia SS, Medeiros FW, Mohan RR, Sinha S, Wilson SE. Topical interleukin-1 receptor antagonist inhibits inflammatory cell infiltration into the cornea. *Exp Eye Res* 2008; 86:753-7. [PMID: 18346730].
30. Yamada J, Dana MR, Sotozono C, Kinoshita S. Local suppression of IL-1 by receptor antagonist in the rat model of corneal alkali injury. *Exp Eye Res* 2003; 76:161-7. [PMID: 12565803].
31. Schönbeck U, Mach F, Libby P. Generation of biologically active IL-1 beta by matrix metalloproteinases: a novel caspase-1-independent pathway of IL-1 beta processing. *J Immunol* 1998; 161:3340-6. [PMID: 9759850].
32. Ma DH, Chen JK, Kim WS, Hao YX, Wu HC, Tsai RJ, Hwang DG, Zhang F. Expression of matrix metalloproteinases 2 and 9 and tissue inhibitors of metalloproteinase 1 and 2 in inflammation-induced corneal neovascularization. *Ophthalmic Res* 2001; 33:353-62. [PMID: 11721189].
33. Mignatti P, Rifkin DB. Plasminogen activators and matrix metalloproteinases in angiogenesis. *Enzyme Protein* 1996; 49:117-37. [PMID: 8797002].
34. Kato T, Kure T, Chang JH, Gabison EE, Itoh T, Itohara S, Azar DT. Diminished corneal angiogenesis in gelatinase A-deficient mice. *FEBS Lett* 2001; 508:187-90. [PMID: 11718713].
35. Kvanta A, Sarman S, Fagerholm P, Seregard S, Steen B. Expression of matrix metalloproteinase-2 (MMP-2) and vascular endothelial growth factor (VEGF) in inflammation-associated corneal neovascularization. *Exp Eye Res* 2000; 70:419-28. [PMID: 10865990].
36. Xing D, Bonanno JA. Effect of cAMP on TGF beta 1-induced corneal keratocyte myofibroblast transformation. *Invest Ophthalmol Vis Sci* 2009; 50:626-33. [PMID: 18936144].
37. Carrington LM, Albon J, Anderson I, Kamma C, Boulton M. Differential regulation of key stages in early corneal wound healing by TGF-beta isoforms and their inhibitors. *Invest Ophthalmol Vis Sci* 2006; 47:1886-94. [PMID: 16638995].

Articles are provided courtesy of Emory University and the Zhongshan Ophthalmic Center, Sun Yat-sen University, P.R. China. The print version of this article was created on 15 December 2023. This reflects all typographical corrections and errata to the article through that date. Details of any changes may be found in the online version of the article.