

Treatment of experimental autoimmune uveoretinitis with peroxisome proliferator-activated receptor α agonist fenofibrate

Miho Osada, Tsutomu Sakai, Kana Kuroyanagi, Hideo Kohno, Hiroshi Tsuneoka

Department of Ophthalmology, Jikei University School of Medicine, Tokyo, Japan

Purpose: The peroxisome proliferator-activated receptor α (PPAR α) agonist has been approved for treating hypercholesterolemia and lipid abnormalities. Researchers have recently discovered that an anti-inflammatory effect of PPAR agonist may have the potential to treat autoimmune disease. This study aims to investigate the therapeutic effects of fenofibrate on experimental autoimmune uveoretinitis (EAU).

Methods: EAU was induced in Lewis rats using bovine S-antigen (S-Ag) peptide. Fenofibrate was suspended in 3% arabic gum and administered orally at a high dose of 100 mg/kg and at a low dose of 20 mg/kg every day. Fenofibrate treatment was initiated after the clinical onset once daily for 14 days. The rats were examined every other day for clinical signs of EAU. The histological scores and delayed-type hypersensitivity (DTH) were evaluated on day 28 post-immunization. Morphologic and immunohistochemical examinations were performed with light and confocal microscopy, respectively. Lymphocyte proliferation was measured with [3H] thymidine incorporation into antigen-stimulated T cells from inguinal lymph nodes.

Results: Clinical and histological scores of EAU were decreased in the fenofibrate-treated groups. The expression of inflammatory cytokines and Müller cell proliferation were inhibited in the fenofibrate-treated groups. DTH was significantly inhibited in the fenofibrate-treated groups, compared with the vehicle-treated groups (controls). Lymphocyte proliferation assay demonstrated decreased proliferation in the presence of 25 mg/ml S-Ag peptide in the fenofibrate-treated groups compared with controls.

Conclusions: The current results indicate that fenofibrate administered orally following clinical onset has therapeutic effect in EAU. Fenofibrate may be useful for treating intraocular inflammation.

Uveitis is a common cause of human visual disability and blindness. Experimental autoimmune uveoretinitis (EAU) is an organ-specific autoimmune disease that serves as an animal model of human uveitis and can be induced by immunization with retinal antigen (Ag; S-Ag or interphotoreceptor retinoid-binding protein [IRBP]) emulsified with complete Freund's adjuvant (CFA) [1]. EAU is a CD4⁺ T cell-mediated disease in which macrophages play an important role as effector cells that generate intraocular inflammation and photoreceptor cell damage [1-3]. Breakdown of the blood-retina barrier leads to inflammatory cell infiltration of the anterior and posterior segments of the eye, followed by irreversible destruction of retinal photoreceptors [4].

Peroxisome proliferator-activated receptors (PPARs) are ligand-activated transcription factors belonging to the nuclear hormone receptor superfamily, which includes steroid, retinoic acid, and thyroid hormone receptors [5]. Three isoforms of PPARs have been identified: PPAR α , PPAR γ , and PPAR β/δ . PPAR α , the first PPAR to be cloned, regulates lipid homeostasis and is a target of the class of drugs known as

fibrates [6-9]. Fibrates, such as fenofibrate and gemfibrozil, are used clinically for treating hyperglycemia and are safe and well tolerated by patients. PPAR α is expressed in immune cells, including macrophages, dendritic cells, and T and B lymphocytes, and PPAR α agonists are thought to play a role in regulating the inflammatory response [10-14]. PPAR α agonists may also regulate inflammation by sustaining expression of the negative regulator nuclear factor of kappa light polypeptide gene enhancer in B-cells inhibitor, alpha (I κ B α), thus preventing nuclear translocation and activation of nuclear factor kappaB (NF- κ B), a major transcription factor involved in initiating proinflammatory immune responses [10,15]. Lovett-Racke et al. have shown that oral administration of PPAR α agonists prevents the development of experimental autoimmune encephalomyelitis (EAE) [16].

The aim of the present study was to investigate the efficacy of treatment with fenofibrate in Lewis rats with EAU. This drug was administered after the first signs of disease development, and the effect was evaluated with clinical and histological scores, immunohistochemistry, lymph node cellular proliferation, and the development of delayed-type hypersensitivity (DTH).

Correspondence to: Tsutomu Sakai, Department of Ophthalmology, Jikei University School of Medicine, 3-25-8 Nishishinbashi, Minato-ku, Tokyo 105-8461, Japan; Phone: +81-3-3433-1111 ex3581; FAX: +81-3-3433-1936; email: tstmski@jikei.ac.jp

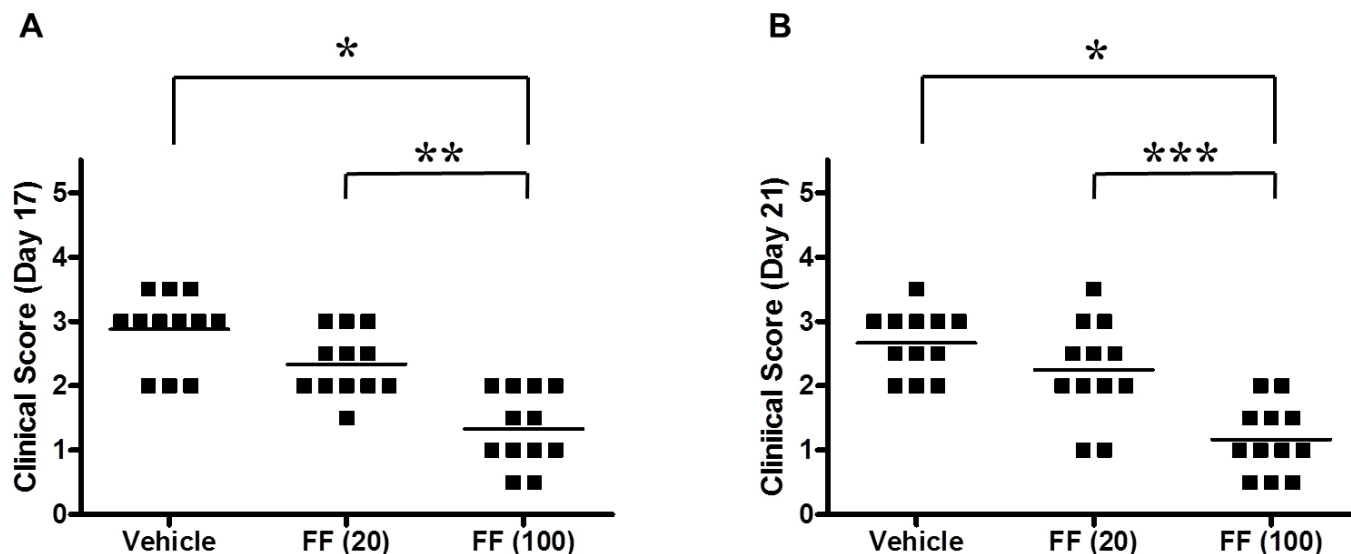


Figure 1. Clinical scores of rats with experimental autoimmune uveoretinitis. Clinical scores for days 17 (A) and 21 (B) post-immunization are shown. The clinical scores of the rats treated with high-dose fenofibrate (FF(100); 100 mg/kg, n=12) were significantly lower than those of the rats treated with vehicle (3% arabic gum, n=12) or low-dose fenofibrate (FF (20); 20 mg/kg, n=12) on days 17 and 21 post-immunization. *, p=0.0001, **, p=0.0007, ***, p=0.0015.

METHODS

Animals and anesthesia: Male Lewis rats weighing 200–250 g (Sankyo Labo Service, Tokyo, Japan) were used in the study. All experiments were conducted in accordance with the Animal Care Committee of the Jikei University School of Medicine and the Association for Research in Vision and Ophthalmology Statement for the Use of Animals in Ophthalmic and Vision Research. Rats were anesthetized with a mixture (1:1) of ketamine hydrochloride (10 mg/kg; Wako Pure Chemicals Industries, Osaka, Japan) and xylazine hydrochloride (4 mg/kg; Wako).

Induction and evaluation of experimental autoimmune uveoretinitis: Each rat was immunized with a subcutaneous injection of 50 µg of bovine S-antigen (S-Ag) peptide 303–320 (DTNLSSTIIKEGIDKTV; purity >95%; Takara-Bio, Ohtsu, Japan), which has been shown to induce EAU [17], emulsified in the same volume of CFA (2 mg/ml) containing *Mycobacterium tuberculosis* H37Ra (Difco Laboratories, Detroit, MI). The rats were examined every other day for clinical signs of EAU and were graded 0–4 for clinical severity, as described previously [18]: grade 0, no inflammation; grade 1, iris vessel engorgement and minimal retinal vasculitis; grade 2, anterior chamber cells and mild retinal vasculitis; grade 3, fibrous exudates at the pupil margin and moderate retinal vasculitis; and grade 4, retroiridal hypopyon and severe retinal vasculitis. Topical 1% tropicamide and 2.5% phenylephrine hydrochloride were instilled to induce mydriasis to observe the fundus. Ocular examination was

conducted using slit-lamp biomicroscopy and an indirect ophthalmoscope. The presence of inflammatory cells or fibrin in the anterior chamber, vessel dilatation, vessel tortuosity, or retinal hemorrhage in the fundus was scored in a blinded fashion by two ophthalmologists (M.O. and T.S.).

Treatment of experimental autoimmune uveoretinitis: Fenofibrate (Lipidil, Daiichi Sankyo, prescription formulation) was dissolved immediately before use in 3% arabic gum (Wako) and administered by oral gavage every day at a high dose of 100 mg/kg per rat and at a low dose of 20 mg/kg per rat. Alternatively, vehicle alone was administered orally daily. The EAU rats treated with vehicle alone were used as positive controls for comparison with the fenofibrate-treated groups. Fenofibrate treatment was initiated on day 14 post-immunization, when the first signs of clinical onset are usually observed. Daily administration was continued until day 27. On day 28, the animals were euthanized following assessment of DTH.

Histopathology and immunohistochemistry: The histopathology and immunohistochemistry methods have been described elsewhere [18,19]. Rats were euthanized with sodium pentobarbital (i.v.; Wako) on day 28 post-immunization, and the enucleated eyes were immersion fixed for 10 min in 4% paraformaldehyde in sodium cacodylate buffer (0.1 N; pH 7.4; Wako). After the cornea and lens were removed, the eyecup was cut into halves. One half of the tissue was stored in the fixative solution, and small areas of the retina were excised and embedded in low-melting point agarose

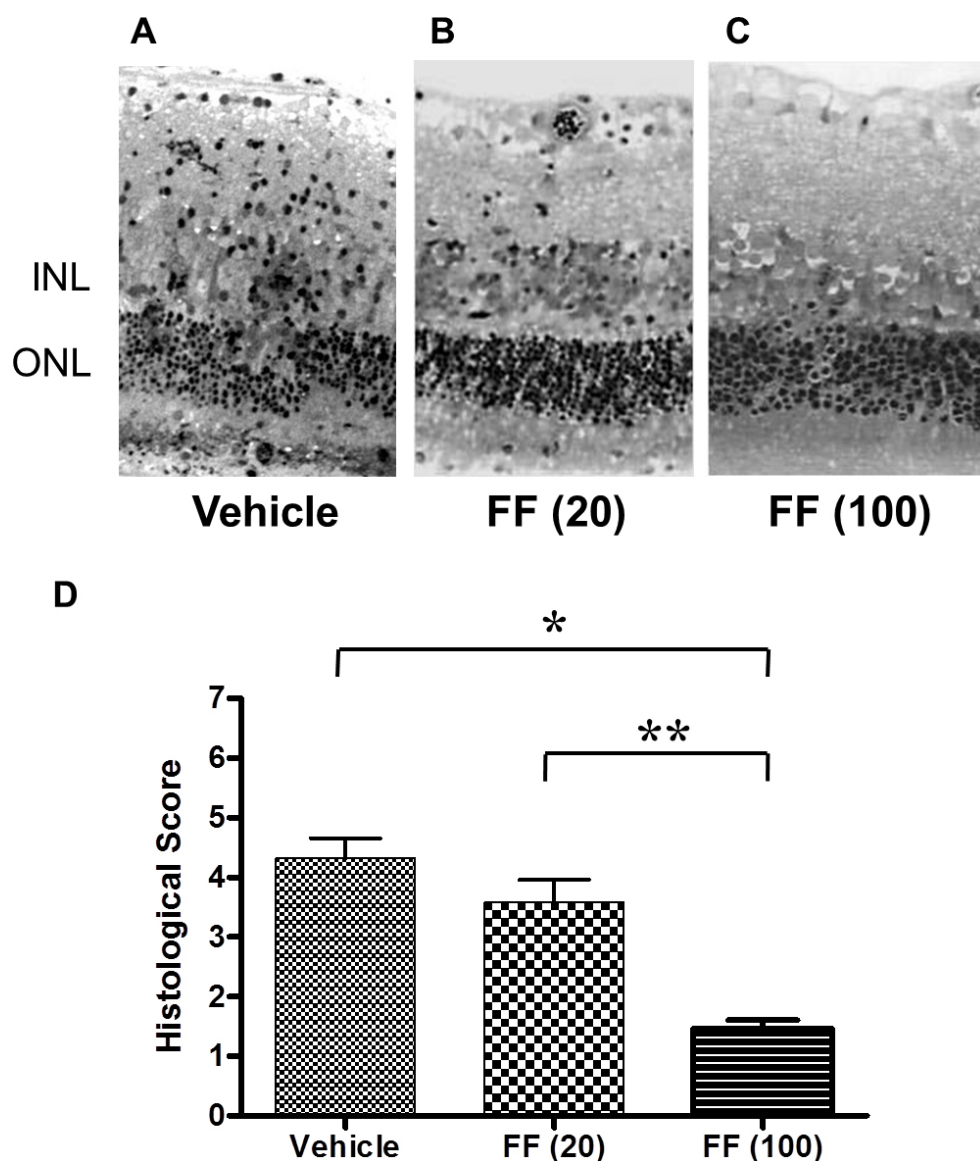


Figure 2. Histopathologic features of the retina and histological scores of rats with experimental autoimmune uveoretinitis. The average histological score of five histological sections from each animal (n=5) was examined. Representative photographs of the groups treated with vehicle (A), low-dose fenofibrate (FF (20); 20 mg/kg) (B), and high-dose fenofibrate (FF (100); 100 mg/kg) (C) on day 28 post-immunization are shown. The vehicle-treated rats had severe posterior uveoretinitis with destruction of the photoreceptor cell layer with inflammatory cell infiltration in the retina. Rats treated with low-dose fenofibrate exhibited mild inflammatory cell infiltration. Rats treated with high-dose fenofibrate exhibited suppression of inflammation and preservation of the photoreceptor layer. INL; inner nuclear layer, ONL; outer nuclear layer (original magnification, $\times 100$). The mean experimental autoimmune uveoretinitis (EAU) histological severity grades of the rats treated with vehicle, low-dose fenofibrate, and high-dose fenofibrate were 4.32 ± 1.65 (n=5), 3.62 ± 1.65 (n=5), and 1.52 ± 1.65 (n=5), respectively. The scores of the rats treated with high-dose fenofibrate (FF(100)) were significantly lower than that

of vehicle- or low-dose fenofibrate-treated rats (D). The results are presented as the mean \pm standard deviation (SD) * p<0.0001 versus vehicle-treated group, ** p<0.0001 versus the low-dose fenofibrate-treated group.

(Sigma-Aldrich, St. Louis, MO) for immunocytochemical analysis with confocal microscopy. The embedded sections were cut on a Vibratome (VT1000S, Leica Microsystems, Heerbrugg, Switzerland) and blocked overnight in normal donkey serum (Jackson ImmunoResearch Laboratories, West Grove, PA; 1:20) at 4 °C. The sections were then incubated overnight at 4 °C on a rotator with the following primary antibodies: mouse monoclonal antibodies (mAb) to interleukin (IL)-6 (R&D Systems, Minneapolis, MN; 1:100), IL-17 (R&D Systems; 1:100), and glutamine synthetase (GS; Chemicon, Temecula, CA; 1:100), and a rabbit polyclonal Ab to vascular endothelial growth factor (VEGF; Santa Cruz Biotechnology, Santa Cruz, CA; 1:100). All antibody solutions were prepared

in PBTA (0.1 M PBS (1X; 140 mM NaCl, 2.7 mM KCl, 10 mM PO_4^{3-} , pH 7.4) containing 0.5% bovine serum albumin [BSA; Fisher Scientific, Pittsburgh, PA], 0.1% Triton X-100 [Boehringer-Mannheim, Indianapolis, IN], and 0.1% sodium azide [Sigma]). Control sections were rinsed in PBTA and then incubated with mouse and rabbit immunoglobulin G (IgG; Sigma). All antibody solutions were made in PBTA containing 0.5% BSA, 0.1% Triton X-100, and 0.1% sodium azide. After rinsing with PBTA, the sections were incubated with Cy3-conjugated donkey anti-mouse IgG (IL-17, GS) or Cy2-conjugated donkey anti-rabbit IgG (IL-6, VEGF; Jackson ImmunoResearch Laboratories) overnight at 4 °C on a rotator. The sections were mounted in mounting medium for

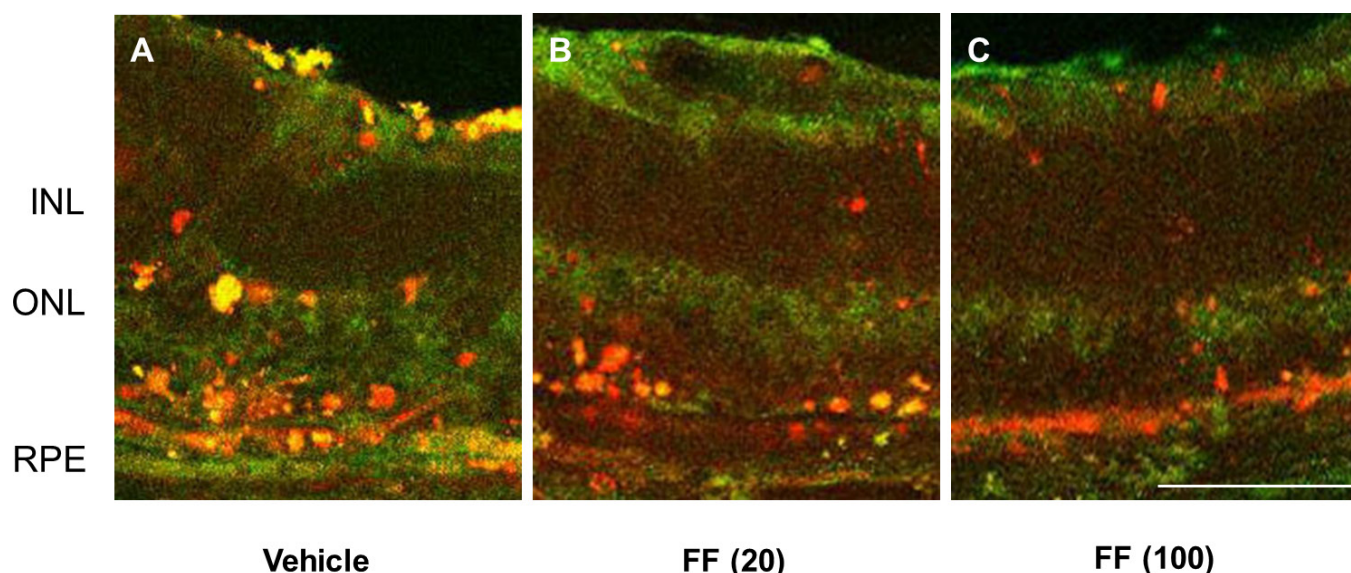


Figure 3. Immunohistochemistry of retinal sections from rats with experimental autoimmune uveoretinitis treated with vehicle (n=4), low-dose fenofibrate (n=4), and high-dose fenofibrate (n=4) on day 28 post-immunization. Marked expression of interleukin (IL)-6 (green) and IL-17 (red) was observed in ocular infiltrative cells in rats treated with vehicle (A). Rats treated with a high dose of fenofibrate showed weak expression of IL-6 and IL-17, and marked decrease in ocular infiltrative cells. INL; inner nuclear layer, ONL; outer nuclear layer, RPE; retinal pigment epithelium. The bar represents 50 μ m.

fluorescence (Vectashield, Vector Laboratories, Burlingame, CA) and viewed on a laser scanning confocal microscope (Laser Scanning System LSM510; Carl Zeiss Meditech, Oberkochen, Germany). For immunohistochemistry, both eyes were evaluated, and five histological sections from each animal (n=4) were examined.

For high-resolution transmission light microscopy analysis, the other half of the eyecup was immersion fixed in 1% glutaraldehyde (Wako) and 1% paraformaldehyde (Wako) in sodium phosphate buffer (0.086 M; pH 7.3) overnight at 4 °C, then fixed in phosphate-buffered osmium tetroxide (2%; Nisshin-EM, Tokyo, Japan) for 1 h, and embedded in epoxy resin (Nisshin-EM). These specimens were sectioned at 1 μ m and stained with toluidine blue (Wako). Both eyes were evaluated. Five histological sections from each animal (n=5) were examined, and the histological severity of EAU was graded semiquantitatively in a blinded fashion by two ophthalmologists (M.O. and T.S.) on a scale of 0–7, as described previously [18,20]: grade 0, no tissue destruction; grades 1–2, destruction of outer segments of rods and cones; grades 3–4, destruction of the outer nuclear layer; grades 5–6 destruction of the inner nuclear layer; and grade 7, destruction of the ganglion cell layer.

Delayed-type hypersensitivity: The DTH response against the S-Ag peptide has been described elsewhere [18,21]. On day 26 post-immunization, the rats received an injection of

200 μ g/20 μ l of S-Ag peptide suspended in PBS into the right ear pinnae. After 48 h, ear swelling was measured using a micrometer (Mitsutoyo, Tokyo, Japan).

Lymphocyte proliferation assay: Lymph node cells (LNCs; 6×10^6 cells/ml) were prepared from control- (vehicle) or fenofibrate-treated rats on day 28 post-immunization, and grown in RPMI-1640 medium (Immuno-Biology Laboratories, Tokyo, Japan). Lymph node cells were pooled within the groups from vehicle- and fenofibrate-treated rats (n=4, each). Duplicate cultures were stimulated in vitro with S-Ag peptide. Cells were unstimulated or stimulated with 1.0, 5.0, and 25.0 μ g/ml S-Ag peptide for 72 h. For the final 18 h, 1 mCi of [methyl-3H] thymidine (ICN, Costa Mesa, CA) was added to each well. The cells were harvested, and [3H] thymidine uptake was determined by measurement of the radioactivity with a Beta-plate reader (Beckman Instruments, Fullerton, CA).

Statistical analysis: We compared the EAU scores, DTH, and lymph node cellular proliferation using the non-parametric Mann–Whitney U-test. All results are expressed as mean \pm standard deviation (SD) in the text and figures. P values less than 0.05 were considered statistically significant.

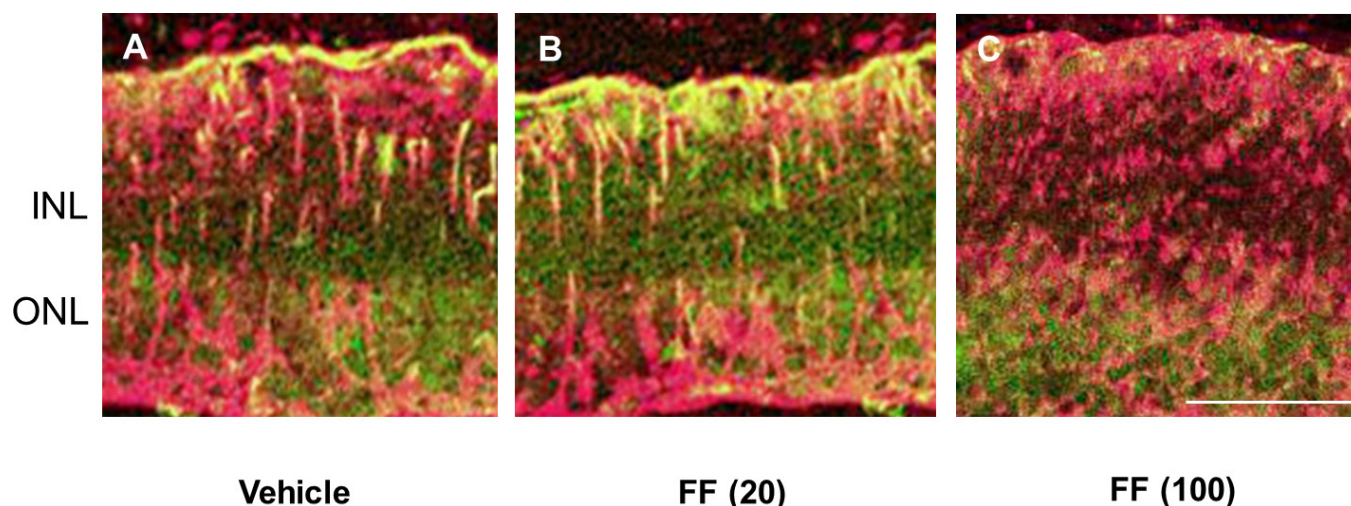


Figure 4. Immunohistochemistry of the retina of rats with experimental autoimmune uveoretinitis. Representative results for expression of vascular endothelial growth factor (VEGF; green) and glutamine synthetase (GS; red) are shown on day 28 post-immunization treated with vehicle (A), low-dose fenofibrate (FF(20); B), and high-dose fenofibrate (FF(100); C). Increased expression of VEGF was observed in Müller cells (A and B). Rats treated with high-dose fenofibrate showed faint expression of VEGF in Müller cells and a marked decrease in ocular infiltrative cells (C). The bar represents 50 μ m.

RESULTS

Clinical and histological assessment: Following induction of EAU, animals were monitored every other day for clinical signs of disease. Clinical scores of day 17 and day 21 post-immunization are shown (Figure 1A,B). The high dose of fenofibrate (100 mg/kg) significantly decreased the clinical score compared with the vehicle-treated group, but the low-dose fenofibrate (20 mg/kg) did not significantly decrease the clinical score on day 17 or 21 post-immunization (Figure 1A,B). The fenofibrate-treated rats exhibited low-grade histological severity (Figure 2A–D). The mean EAU histological severity grade of the high-dose fenofibrate-treated rats was significantly low compared with the control rats and the low-dose fenofibrate-treated rats (Figure 2D). Control rats exhibited severe posterior uveitis with infiltration of inflammatory cells in the retina and destruction of the photoreceptor cell layer (Figure 2A). Rats treated with high-dose fenofibrate (100 mg/kg) exhibited suppression of inflammation and preservation of the photoreceptor cell layer, the target of the immune response. Meanwhile, photoreceptor destruction was not prevented completely by oral fenofibrate at 20 mg/kg or 100 mg/kg, since the treatment was started when the first sign of clinical onset was seen.

Immunohistochemistry: Representative images of immunohistochemical staining of the retinas of the rats with EAU on day 28 post-immunization are shown in Figure 3. In rats with EAU treated with vehicle alone, expression of IL-6 (green) and IL-17 (red) was found in all layers of the retina (Figure

3A). Most of the infiltrated cells expressed IL-17. Treatment with low-dose fenofibrate (20 mg/kg) slightly reduced the number of infiltrated cells and the level of cytokines in the outer retina (Figure 3B). In rats with EAU treated with high-dose fenofibrate (100 mg/kg), expression of IL-17 and infiltration of cells were largely decreased in the retina (Figure 3C). In Figure 3A–C, there was some light immunoreactivity with the IL-17 antibody in the retinal pigment epithelium and IL-6 antibody in the inner limiting membrane, but this was the same in all preparations.

Immunohistochemical results for retinas collected on day 28 post-immunization from rats treated with vehicle and fenofibrate are shown in Figure 4. In the vehicle- or low-dose fenofibrate-treated retinas, GS (red) and VEGF (green) were expressed in activated Müller cells (Figure 4A,B). Rats treated with high-dose fenofibrate (100 mg/kg) showed less VEGF expression (Figure 4C).

Effects of fenofibrate on systemic immune responses: On day 28 post-immunization, the ears of the rats were challenged with S-Ag peptide. The rats treated with high-dose fenofibrate exhibited significant inhibition of ear swelling 48 h after the S-Ag peptide challenge compared with the vehicle-treated rats (Figure 5).

The lymphocyte proliferation test (Figure 6) demonstrated that the high dose of fenofibrate induced a decrease in lymphocyte proliferation in the presence of 25 μ g/ml S-Ag peptide compared with the vehicle-treated rats.

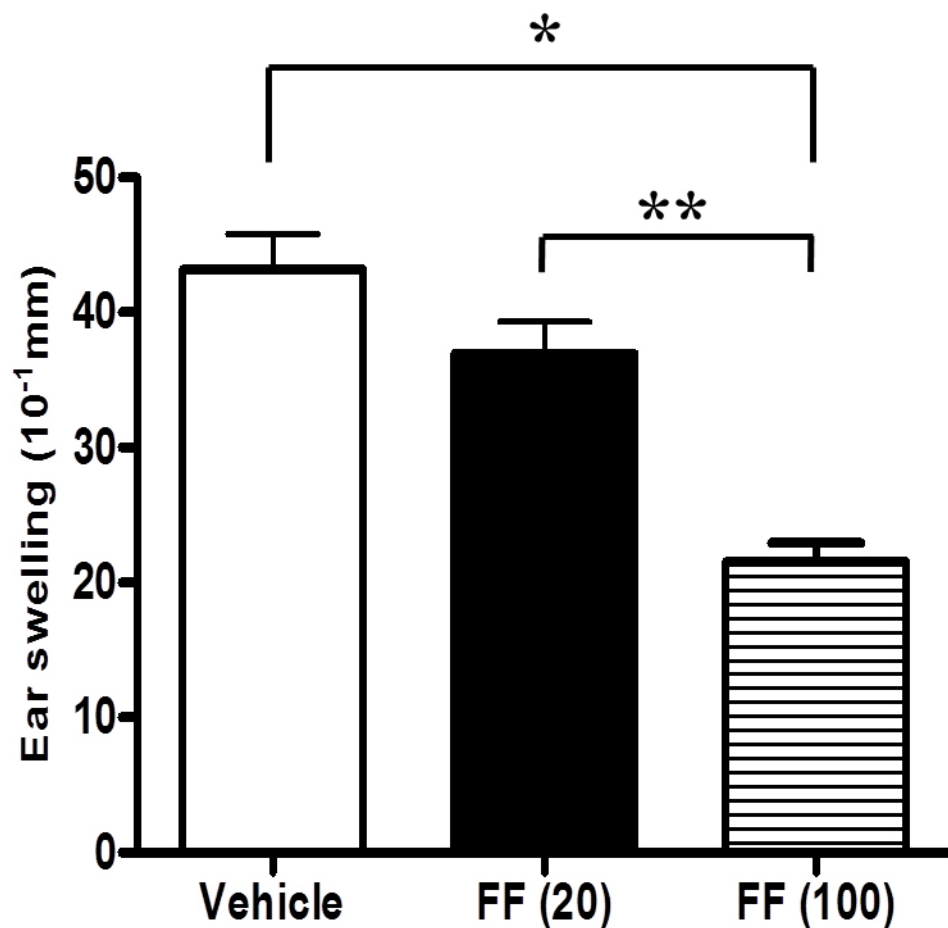


Figure 5. Delayed-type hypersensitivity responses to S-antigen peptide. The delayed-type hypersensitivity (DTH) responses to the S-antigen (S-Ag) peptide in rats with experimental autoimmune uveoretinitis (EAU) treated with vehicle (n=10), low-dose fenofibrate (FF(20)), and high-dose fenofibrate (FF(100)) were 4.32 ± 0.92 , 3.69 ± 0.82 , and 2.15 ± 0.49 mm, respectively. Rats treated with a high dose of fenofibrate exhibited significant inhibition of ear swelling 48 h after S-Ag peptide challenge compared with the vehicle- or low-dose fenofibrate-treated rats. The results are presented as the mean \pm standard deviation (SD). * $p < 0.0001$ versus vehicle-treated group, ** $p = 0.0003$ versus low-dose fenofibrate-treated group.

DISCUSSION

In the present study, our data revealed that oral fenofibrate inhibited the course of the disease in an animal model of uveoretinitis, due to anti-inflammatory and immunomodulatory effects, even though the administration of the drugs was initiated after disease induction. Clinical and histopathological data showed that administration of fenofibrate resulted in a significant anti-inflammatory effect. In addition, the DTH and LNC proliferation data demonstrated that fenofibrate exhibited immunomodulatory effects in EAU. Thus, fenofibrate had a therapeutic effect with partial preservation of the retinal photoreceptors.

PPAR α and RXR agonists inhibit microglial and astrocyte production of nitric oxide (NO), IL-1 β , tumor necrosis factor- α (TNF- α), IL-6, and monocyte chemoattractant protein-1 (MCP-1) in EAE, an animal model of multiple sclerosis [22,23]. PPAR α -deficient mice have abnormally prolonged responses to inflammatory stimuli such as arachidonic acid and leukotrienes [24], and expression of IL-6, vascular cell adhesion molecule (VCAM), and

cyclooxygenase-2 in response to cytokine activation can be inhibited by PPAR α ligands [25]. PPAR α ligands have also been shown to decrease NF- κ B activation and IL-12 and IL-6 production in aged mice [26], and may inhibit functional expression of NF- κ B, in part by augmenting expression of I κ B α [27]. PPAR α agonists may mediate protection against EAE in part by repressing transcription factors such as NF- κ B and T-bet, which regulate Th1 or Th17 inflammatory genes, as demonstrated for PPARs [16,28-30].

IL-6 and IL-17 are likely to play major roles in the pathogenesis of EAU [31,32]. IL-6 is required for differentiation of Th17 cells, a recently discovered IL-17-producing helper CD4⁺ T-cell subset [33,34]. Differentiated Th17 cells may recruit inflammatory cells into the retina, and these cells then produce proinflammatory cytokines and chemokines [32]. In this study, we found that fenofibrate inhibited production of increased IL-6 and IL-17 in EAU rats. These cytokines contribute to the development of EAU and retinal degeneration secondary to inflammation, and inhibition of their production may offer an important advantage for visual outcome.

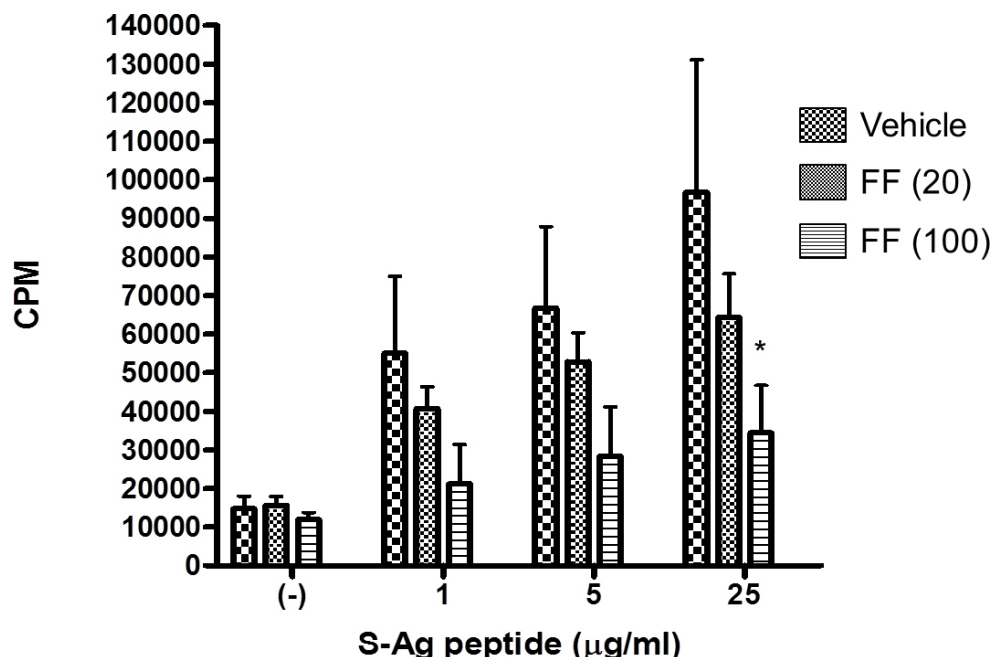


Figure 6. Proliferative response to the S-antigen peptide in lymph node cells collected from rats treated with vehicle (n=4), low-dose fenofibrate (20 mg/kg, n=4), and high-dose fenofibrate (100 mg/kg, n=4) on day 28 post-immunization. The lymphocyte proliferation test demonstrated that high-dose fenofibrate treatment induced a decrease in lymphocyte proliferation in the presence of 25 mg/ml S-antigen (S-Ag) peptide compared with vehicle-treated groups. *p=0.0008 versus vehicle-treated group.

We also found that fenofibrate inhibits Müller glia production of VEGF in EAU. VEGF is an inflammatory cytokine that induces ocular neovascularization and vascular hyperpermeability, which result in retinal or choroidal neovascularization (CNV) secondary to uveitis and uveitic edema. Anti-VEGF therapy has efficacy for CNV secondary to uveitis [35-38]. Fine et al. [39] found increased VEGF levels in the aqueous humor of patients with uveitic cystoid macular edema (CME), and Vinore et al. [40] showed that VEGF expression is upregulated in the inner retina of EAU rats. In the current study, we showed that fenofibrate inhibited the increase in VEGF expression in EAU rats. Since CNV and CME secondary to uveitis cause significant visual impairment, VEGF expression decreased by fenofibrate may result in a significant improvement in vision.

Oral administration of fenofibrate (100 mg/kg) after disease induction ameliorated the disease of EAU in Lewis rats. However, the dose for such effects is far greater than that for controlling hypercholesterolemia in adults. In a recent clinical study, fenofibrate exhibited an anti-inflammatory effect for rheumatoid arthritis at a dose of 145 mg/day [41]. Although the human therapeutic dose of fenofibrate for inhibiting intraocular inflammation has still not been determined, the current study may suggest that the higher dose should be used in humans for inhibiting intraocular inflammation.

The results of this study establish that EAU is ameliorated by administration of fenofibrate. This finding is important because it suggests that PPAR α agonists could be used

clinically for treatment of immune-mediated inflammatory diseases such as autoimmune uveitis. PPAR α agonists are a class of drugs with a favorable safety profile that could improve the quality of life of patients with autoimmune uveitis if proven to be effective in reducing disease severity. The suppressive effect of oral fenofibrate on EAU suggests that fenofibrate may be an effective therapy for autoimmune uveitis. The insights gained from dissecting the mechanism of action of fenofibrate in EAU could also be used for development of new drugs with fewer side effects for treatment of immune-mediated inflammatory diseases.

ACKNOWLEDGMENTS

We sincerely thank Dr. Saburo Saito, for helping with the lymphocyte proliferation assay analysis in this study. Funding: This study was supported by grants from the Vehicle Racing Commemorative Foundation.

REFERENCES

1. Caspi RR. Th1 and Th2 responses in pathogenesis and regulation of experimental autoimmune uveoretinitis. *Int Rev Immunol* 2002; 21:197-208. [PMID: 12424843].
2. Forrester JV, Huitinga I, Lumsden L, Dijkstra CD. Marrow-derived activated macrophages are required during the effector phase of experimental autoimmune uveoretinitis in rats. *Curr Eye Res* 1998; 17:426-37. [PMID: 9561835].
3. Pouvreau I, Zech JC, Thillaye-Goldenberg B, Naud MC, Van Rooijen N, de Kozak Y. Effect of macrophage depletion by

- liposomes containing dichloromethylene- diphosphonate on endotoxin-induced uveitis. *J Neuroimmunol* 1998; 86:171-81. [PMID: 9663563].
4. Luna JD, Chan CC, Derevanik NL, Mahlow J, Chiu C, Peng B, Tobe T, Campochiaro PA, Vinore SA. Blood-retinal barrier (BRB) breakdown in experimental autoimmune uveoretinitis: comparison with vascular endothelial growth factor, tumor necrosis factor alpha, and interleukin-1beta-mediated breakdown. *J Neurosci Res* 1997; 49:268-80. [PMID: 9260738].
 5. Desvergne B, Wahli W. Peroxisome proliferator-activated receptors: nuclear control of metabolism. *Endocr Rev* 1999; 20:649-88. [PMID: 10529898].
 6. Issemann I, Green S. Activation of a member of the steroid hormone receptor superfamily by peroxisome proliferators. *Nature* 1990; 347:645-50. [PMID: 2129546].
 7. Issemann I, Prince RA, Tugwood JD, Green S. The peroxisome proliferator-activated receptor: retinoid X receptor heterodimer is activated by fatty acids and fibrates hypolipidaemic drugs. *J Mol Endocrinol* 1993; 11:37-47. [PMID: 8240670].
 8. Lehmann JM, Lenhard JM, Oliver BB, Ringold GM, Kliewer SA. Peroxisome proliferator-activated receptors α and γ are activated by indo-methacin and other non-steroidal anti-inflammatory drugs. *J Biol Chem* 1997; 272:3406-10. [PMID: 9013583].
 9. Forman BM, Chen J, Evans RM. Hypolipidemic drugs, polyunsaturated fatty acids, and eicosanoids are ligands for peroxisome proliferator-activated receptors α and δ . *Proc Natl Acad Sci USA* 1997; 94:4312-4317. [PMID: 9113986].
 10. Jones DC, Ding X, Daynes RA. Nuclear receptor PPAR α is expressed in resting murine lymphocytes: the PPAR α in T and B lymphocytes is both transactivation and transrepression competent. *J Biol Chem* 2002; 277:6838-45. [PMID: 11726654].
 11. Devchand PR, Keller H, Peters JM, Vazquez M, Gonzalez FJ, Wahli W. The PPAR α -leukotriene B $_4$ pathway to inflammation control. *Nature* 1996; 384:39-43. [PMID: 8900274].
 12. Cunard R, DiCampli D, Archer DC, Stevenson JL, Ricote M, Glass CK, Kelly CJ. WY14,643, a PPAR α ligand, has profound effects on immune responses in vivo. *J Immunol* 2002; 169:6806-12. [PMID: 12471112].
 13. Delerive P, De Bosscher K, Besnard S, Vanden Berghe W, Peters JM, Gonzalez FJ, Fruchart JC, Tedgui A, Haegeman G, Staels B. Peroxisome proliferator-activated receptor α negatively regulates the vascular inflammatory gene response by negative cross-talk with transcription factors NF- κ B and AP-1. *J Biol Chem* 1999; 274:32048-54. [PMID: 10542237].
 14. Chinetti G, Lestavel S, Bocher V, Remaley AT, Neve B, Torra IP, Teissier E, Minnich A, Jaye M, Duverger N, Brewer HB, Fruchart JC, Clavey V, Staels B. PPAR- α and PPAR- γ activators induce cholesterol removal from human macrophage foam cells through stimulation of the ABCA1 pathway. *Nat Med* 2001; 7:53-8. [PMID: 11135616].
 15. Delerive P, Gervois P, Fruchart JC, Staels B. Induction of I κ B α expression as a mechanism contributing to the anti-inflammatory activities of peroxisome proliferator-activated receptor- α activators. *J Biol Chem* 2000; 275:36703-7. [PMID: 10980195].
 16. Lovett-Racke AE, Hussain RZ, Northrop S, Choy J, Rocchini A, Matthes L, Chavis JA, Diab A, Drew PD, Racke MK. Peroxisome proliferators-activated receptor α agonists as therapy for autoimmune disease. *J Immunol* 2004; 172:5790-8. [PMID: 15100326].
 17. Donoso LA, Merryman CF, Shinohara T, Dietzschold B, Wistow G, Craft C, Morley W, Henry RT. S-antigen: identification of the MAbA9-C6 monoclonal antibody binding site and the uveitopathogenic sites. *Curr Eye Res* 1986; 5:995-1004. [PMID: 3492336].
 18. Sakai T, Kohno H, Ishihara T, Higaki M, Saito S, Matsushima M, Mizushima Y, Kitahara K. Treatment of experimental autoimmune uveoretinitis with poly(lactic acid) nanoparticles encapsulating betamethasone phosphate. *Exp Eye Res* 2006; 82:657-63. [PMID: 16360654].
 19. Kohno H, Sakai T, Kitahara K. Induction of nestin, Ki-67, and cyclin D1 expression in Muller cells after laser injury in adult rat retina. *Graefes Arch Clin Exp Ophthalmol* 2006; 244:90-5. [PMID: 15983812].
 20. Verwaerde C, Naud MC, Delanoye A, Wood M, Thillaye-Goldenberg B, Auriault C, de Kozak Y. Ocular transfer of retinal glial cells transduced ex vivo with adenovirus expressing viral IL-10 or CTLA4-Ig inhibits experimental autoimmune uveoretinitis. *Gene Ther* 2003; 10:1970-81. [PMID: 14528321].
 21. Inoki T, Yamagami S, Sakai R, Isobe M, Tsuru T, Kawashima H. Suppression of experimental autoimmune uveoretinitis by anti-alpha-beta TCR monoclonal antibody. *Jpn J Ophthalmol* 2002; 46:518-24. [PMID: 12457910].
 22. Xu J, Storer PD, Chavis JA, Racke MK, Drew PD. Agonists for the peroxisome proliferator-activated receptor- α and the retinoid X receptor inhibit inflammatory responses of microglia. *J Neurosci Res* 2005; 81:403-11. [PMID: 15968640].
 23. Xu J, Chavis JA, Racke MK, Drew PD. Peroxisome proliferator-activated receptor- α and retinoid X receptor agonists inhibit inflammatory responses of astrocytes. *J Neuroimmunol* 2006; 176:95-105. [PMID: 16764943].
 24. Devchand PR, Keller H, Peters JM, Vazquez M, Gonzalez FJ, Wahli W. The PPAR α -leukotriene B $_4$ pathway to inflammation control. *Nature* 1996; 384:39-43. [PMID: 8900274].
 25. Delerive P, De Bosscher K, Besnard S, Vanden Berghe W, Peters JM, Gonzalez FJ, Fruchart JC, Tedgui A, Haegeman G, Staels B. Peroxisome proliferator-activated receptor α negatively regulates the vascular inflammatory gene response by negative cross-talk with transcription factors NF- κ B and AP-1. *J Biol Chem* 1999; 274:32048-54. [PMID: 10542237].
 26. Spencer NF, Poynter ME, Im SY, Daynes RA. Constitutive activation of NF- κ B in an animal model of aging. *Int Immunol* 1997; 9:1581-8. [PMID: 9352364].

27. Delerive P, Gervois P, Fruchart JC, Staels B. Induction of IkB α expression as a mechanism contributing to the anti-inflammatory activities of peroxisome proliferator-activated receptor- α activators. *J Biol Chem* 2000; 275:36703-7. [PMID: 10980195].
28. Cunard R, Eto Y, Muljadi JT, Glass CK, Kelly CJ, Ricote M. Repression of IFN- γ expression by peroxisome proliferator-activated receptor- γ . *J Immunol* 2004; 172:7530-6. [PMID: 15187132].
29. Pascual G, Fong AL, Ogawa S, Gamliel A, Li AC, Perissi V, Rose DW, Willson TM, Rosenfeld MG, Glass CK. A SUMOylation-dependent pathway mediates transrepression of inflammatory response genes by PPAR- γ . *Nature* 2005; 437:759-63. [PMID: 16127449].
30. Ogawa S, Lozach J, Benner C, Pascual G, Tangirala RK, Westin S, Hoffmann A, Subramaniam S, David M, Rosenfeld MG, Glass CK. Molecular determinants of cross-talk between nuclear receptors and toll-like receptors. *Cell* 2005; 122:707-21. [PMID: 16143103].
31. Amadi-Obi A, Yu CR, Liu X, Mahdi RM, Clarke GL, Nussenblatt RB, Gery I, Lee YS, Egwuagu CE. TH17 cells contribute to uveitis and scleritis and are expanded by IL-2 and inhibited by IL-27/STAT1. *Nat Med* 2007; 13:711-8. [PMID: 17496900].
32. Yoshimura T, Sonoda KH, Ohguro N, Ohsugi Y, Ishibashi T, Cua DJ, Kobayashi T, Yoshida H, Yoshimura A. Involvement of Th17 cells and the effect of anti-IL-6 therapy in autoimmune uveitis. *Rheumatology* 2009; 48:347-54. [PMID: 19164426].
33. Bettelli E, Carrier Y, Gao W, Korn T, Strom TB, Oukka M, Weiner HL, Kuchroo VK. Reciprocal developmental pathways for the generation of pathogenic effector TH17 and regulatory T cells. *Nature* 2006; 441:235-8. [PMID: 16648838].
34. Mangan PR, Harrington LE, O'Quinn DB, Helms WS, Bullard DC, Elson CO, Hatton RD, Wahl SM, Schoeb TR, Weaver CT. Transforming growth factor-beta induces development of the T(H)17 lineage. *Nature* 2006; 441:231-4. [PMID: 16648837].
35. Adán A, Mateo C, Navarro R, Bitrian E, Casaroli-Marano RP. Intravitreal bevacizumab (avastin) injection as primary treatment of inflammatory choroidal neovascularization. *Retina* 2007; 27:1180-6. [PMID: 18046222].
36. Tran TH, Fardeau C, Terrada C, Ducos De Lahitte G, Bodaghi B, Lehoang P. Intravitreal bevacizumab for refractory choroidal neovascularization (CNV) secondary to uveitis. *Graefes Arch Clin Exp Ophthalmol* 2008; 246:1685-92. [PMID: 18682970].
37. Fine HF, Zhitomirsky I, Freund KB, Barile GR, Shirkey BL, Samson CM, Yannuzzi LA. Bevacizumab (avastin) and ranibizumab (lucentis) for choroidal neovascularization in multifocal choroiditis. *Retina* 2009; 29:8-12. [PMID: 18784620].
38. Wu L, Evans T, Saravia M, Schlaen A, Couto C. Intravitreal bevacizumab for choroidal neovascularization secondary to Vogt-Koyanagi-Harada syndrome. *Jpn J Ophthalmol* 2009; 53:57-60. [PMID: 19184312].
39. Fine HF, Baffi J, Reed GF, Csaky KG, Nussenblatt RB. Aqueous humor and plasma vascular endothelial growth factor in uveitis-associated cystoid macular edema. *Am J Ophthalmol* 2001; 132:794-6. [PMID: 11704050].
40. Vinorez SA, Chan CC, Vinorez MA, Matteson DM, Chen YS, Klein DA, Shi A, Ozaki H, Campochiaro PA. Increased vascular endothelial growth factor (VEGF) and transforming growth factor β (TGF β) in experimental autoimmune uveoretinitis: upregulation of VEGF without neovascularization. *J Neuroimmunol* 1998; 89:43-50. [PMID: 9726824].
41. Shirinsky I, Polovnikova O, Kalinovskaya N, Shirinsky V. The effects of fenofibrate on inflammation and cardiovascular markers in patients with active rheumatoid arthritis: a pilot study. *Rheumatol Int* 2013; 33:3045-8. [PMID: 23263548].

Articles are provided courtesy of Emory University and the Zhongshan Ophthalmic Center, Sun Yat-sen University, P.R. China. The print version of this article was created on 4 November 2014. This reflects all typographical corrections and errata to the article through that date. Details of any changes may be found in the online version of the article.