



Expression of stem cells markers in ocular hemangioblastoma associated with von Hippel-Lindau (VHL) Disease

Chi-Chao Chan,¹ Emily Y. Chew,¹ Defen Shen,¹ Joseph Hackett,¹ Zhengping Zhuang²

¹National Eye Institute and ²National Institute of Neurological Disorders and Strokes, National Institutes of Health, Bethesda, MD

Purpose: To better understand the histogenesis of ocular hemangioblastomas associated with von Hippel-Lindau (VHL) disease.

Methods: We found that co-expression of Epo and EpoR may mediate developmental stagnation and induce proliferation of hemangioblastoma. All lesions were frozen and/or fixed in formalin and embedded in paraffin. The specimens were sectioned and subjected to routine histology, immunohistochemistry and molecular analyses. Avidin-biotin-complex immunoperoxidase was used to evaluate the expression of erythropoietin (Epo), Epo receptor (EpoR), CD31, CD34, CD117, and CD133. Ocular hemangioblastoma cells were microdissected in order to determine expression of *Epo* and *EpoR* transcripts using reverse transcription-polymerase chain reaction.

Results: Tumorlet-like cells were identified in retinal and optic nerve hemangioblastomas. Co-expression of Epo and EpoR at both protein and messenger levels was detected in many hemangioblastoma cells. In addition, ocular VHL lesions expressed several stem cell markers including CD133 to various degrees.

Conclusions: The data suggest that VHL disease-associated ocular hemangioblastomas are comprised of developmentally arrested stem cells including hemangioblasts, endothelial, and neuronal progenitor cells. We found that co-expression of Epo and EpoR may not only mediate developmental stagnation, but may also induce proliferation. Suppression of the growth of AC133/CD133 positive stem cells might be considered as one of the therapeutic targets for VHL-associated hemangioblastoma.

von Hippel-Lindau disease (VHL) is an autosomal dominant, multisystem neoplastic syndrome that results from a germline mutation in the *VHL* gene [1,2]. Germline mutations in the *VHL* gene lead to the development of several tumors and cysts in many organs. Affected individuals are at risk of developing retinal and CNS hemangioblastomas, endolymphatic sac tumors, renal cysts, clear cell carcinomas, pheochromocytomas, pancreatic cysts, neuroendocrine tumors, epididymal cystadenomas, and broad ligament cystadenomas [3-8]. Retinal and CNS hemangioblastomas are the most common, and are most frequently, the earliest manifestations of VHL.

VHL, a tumor suppressor gene, is located at chromosome 3p25.5 [9,10]. According to Knudson's two-hit hypothesis, tumor formation is initiated first by inactivation of the wild-type *VHL* allele [11,12]. The ensuing loss of VHL protein function interferes with the formation of the VHL protein complex (VHL protein bound with other proteins including elongin B, elongin C, and cullin 2). This protein complex determines the ubiquitin-dependent proteolysis of large cellular proteins. The aberrant formation of the VHL protein complex induces the cell to upregulate the hypoxia-inducible factor (HIF) signaling pathway thereby resulting in overexpression of several hypoxia-inducible genes such as vascular endothelial growth

factor (VEGF), erythropoietin (Epo), and platelet derived growth factor (PDGF) [13,14]. We have also previously demonstrated abundant expression of HIF, ubiquitin, and VEGF in VHL-associated retinal and optic nerve hemangioblastomas [15,16].

The roles played by Epo and erythropoietin receptor (EpoR) in the pathogenesis of VHL have been investigated [17,18]. Similar to VEGF, VHL protein may negatively regulate Epo in the non-hypoxic microenvironment of a hemangioblastoma [19,20]. Some rare VHL patients have polycythemia, a condition which has previously been attributed to Epo production by VHL cells [21]. Some polycythemic cases with high Epo levels, such as patients with Chuvah polycythemia, have been found to carry a mutation at the VHL allele [22-25]. Mesenchymal tumorlets composed of poorly differentiated small cells with prominent dark nuclei and little cytoplasm are frequently found in CNS hemangioblastomas [26]. Recently, it has been suggested that arrested angioblast cells, such as tumorlets, along with co-expression of Epo and EpoR may be a developmental origin of hemangioblastomas in the CNS [18,26]. In this study, we examined the expression of Epo, EpoR, and other stem cell markers in VHL-associated retinal hemangioblastomas.

METHODS

Ocular hemangioblastoma lesions from four eyes and two optic nerves were collected from six patients with familiar hereditary VHL disease. All patients were examined clinically by one of the authors (EYC) at the National Eye Institute (NEI).

Correspondence to: Chi-Chao Chan, MD, Building 10, Room 10N103, NIH/NEI, 10 Center Drive, Bethesda, MD, 20892-1857; Phone: (301) 496-0417; FAX: (301) 402-8664; email: chanc@nei.nih.gov

Both the National Cancer Institute and NEI Institutional Review Boards approved this study for human subjects in adherence with the tenets of the Declaration of Helsinki.

All pathological specimens (eyes and optic nerves) were frozen and/or fixed in formalin. The frozen portions were embedded in optimal cutting temperature (OCT; Sakura Tissue Teck, Torrance, CA) compound and the formalin-fixed portions were embedded in paraffin. The specimens were then sectioned through the lesions and subjected to routine histology, immunohistochemistry, and molecular analyses as described previously [15]. The avidin-biotin-complex immunoperoxidase technique was applied to the frozen sections. The primary antibodies were against Epo (Oncogen, Cambridge, MA), EpoR (CalBioChem, Cambridge, MA), CD31 (Biodesign, Kennebunk, ME), CD34 (Becton Dickinson, San Jose, CA), CD117 (Biodesign), CD133 (Miltenvi Biotec, Auburn, CA), and control IgG. The second-

ary antibodies were biotin-conjugated horse anti-mouse IgGs. The substrate was an avidin-biotin-peroxidase complex (Vector Labs, Burlingame, CA), the chromogene used was diaminobenzidine, and the counterstaining is methyl green. The positive color should be black bluish.

The hemangioblastoma cells were carefully microdissected from the frozen sections for *Epo* and *EpoR* mRNA using reverse transcription-polymerase chain reaction. Briefly, RNA was isolated from manually collected hemangioblastoma cells or by using the PicoPure RNA isolation kit (Arcturus, Mountain View, CA). The reverse transcription reaction was performed using Superscript II RNase H Reverse Transcriptase (Life Technologies, Rockville, MD). The PCR primers for *Epo* were sense, 5'-TCT ATG CCT GGA AGA GGA TGG AGG TCG-3' and antisense, 5'-TGC GGA AAG TGT CAG CAG TGA TTG TTC-3'. For *EpoR*, there primers were sense, 5'-CAC AAG GGT AAC TTC CAG CTG TGG

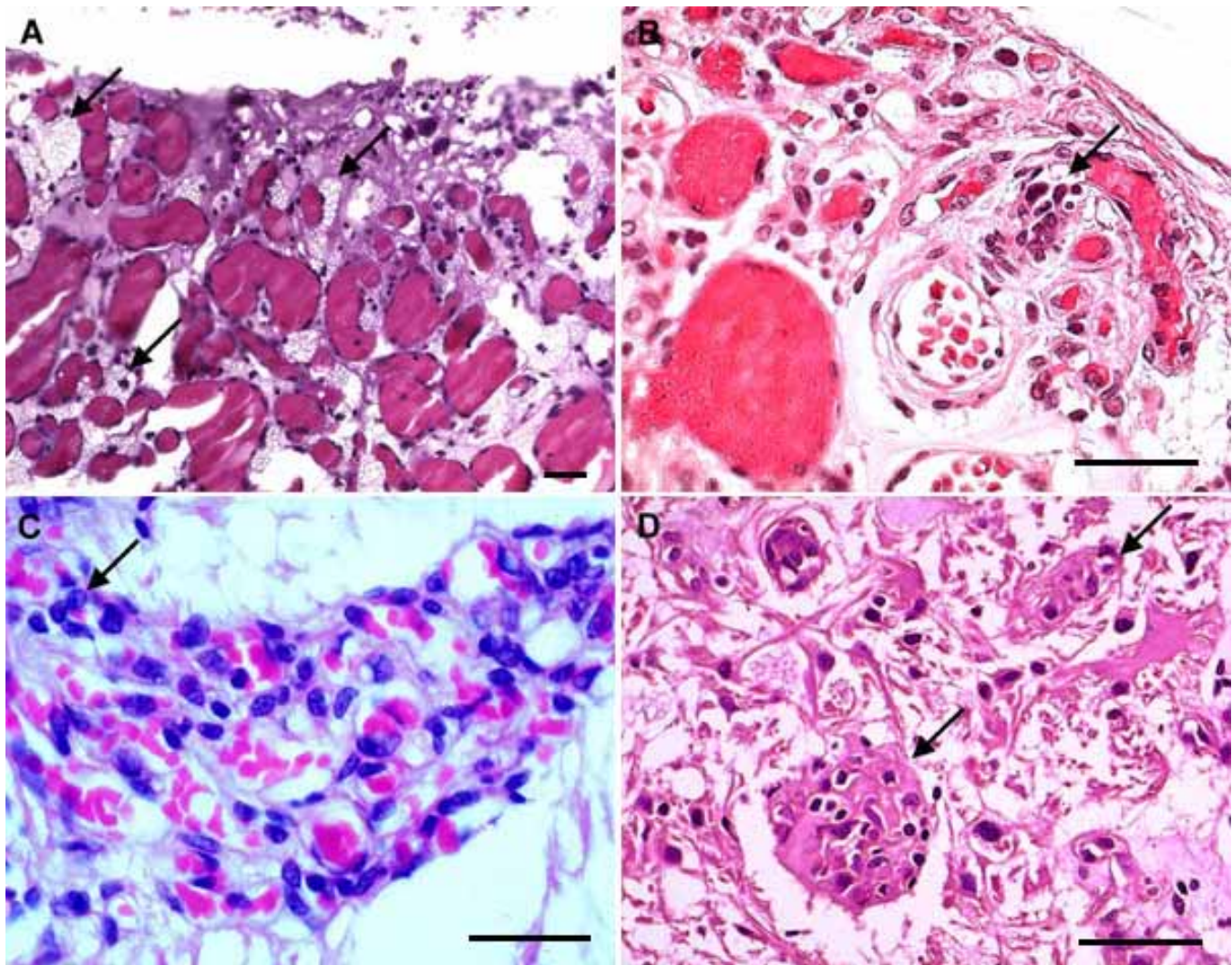


Figure 1. Tumorlet cells in ocular hemangioblastoma. **A:** A classical VHL hemangioblastoma was composed of many vacuolated "stroma" cells (arrows) located between small vessels. **B:** Small tumorlet cells (arrow) were located adjacent to well-defined retinal vessels. **C:** Isolated small cells or tumorlet-like cells (arrow) were observed in a retinal hemangioblastoma. **D:** Several islands of tumorlets (arrows) are identified in an optic nerve hemangioblastoma. Sections were stained with hematoxylin & eosin; the original magnifications were 400x. The scale bars represent 50 μ m.

CTG TA-3' and antisense, 5'-CAT TTG TCC AGC ACC AGA TAG GTA TCC TGG-3'. The PCR reaction mixture contained cDNA, 400 nM of ^{32}P labeled sense and antisense primer, 400 nM of dATP, dCTP, dGTP, and dTTP, and 0.5 unit of AmpliTag Gold Polymerase (Perkin Elmer, Branchburg, NJ) in a final volume of 10 μl of 1 X Tag polymerase buffer containing 1.5 mM MgCl_2 . The PCR was carried out for 40 cycles at 94 °C for 45 s, 63 °C for 1 min and 72 °C for 2 min. The PCR products were visualized following polyacrylamide gel electrophoresis and autoradiography.

RESULTS

Tumorlet-like cells in ocular VHL hemangioblastomas: The four eyes and two optic nerves revealed classic hemangioblastomas with characteristic features of VHL associated tumors. The ocular lesions were best visualized in the

formalin-fixed, paraffin-embedded sections. Microdissected hemangioblastoma cells showed loss of heterozygosity at the VHL gene locus in all six specimens. This finding confirmed our previous reports of VHL gene deletion in ocular VHL lesions [15,16,27].

The hemangioblastomas were characterized by an admixture of small capillary-like vascular channels surrounded by large vacuolated cells (Figure 1A, Figure 2A, and Figure 3A) and small cells with prominent nuclei and scanty cytoplasm without vacuolation (Figure 1B-D). The presence of small capillary-like vascular channels surrounded by large vacuolated cells is the main morphology observed in hemangioblastomas [4,15,16,27]. The small cells shared similar morphology to the "tumorlet" cells seen in CNS hemangioblastoma [26]. However, unlike CNS tumorlet cells, these cells were closely associated with, or adjacent to, either small retinal vessels or

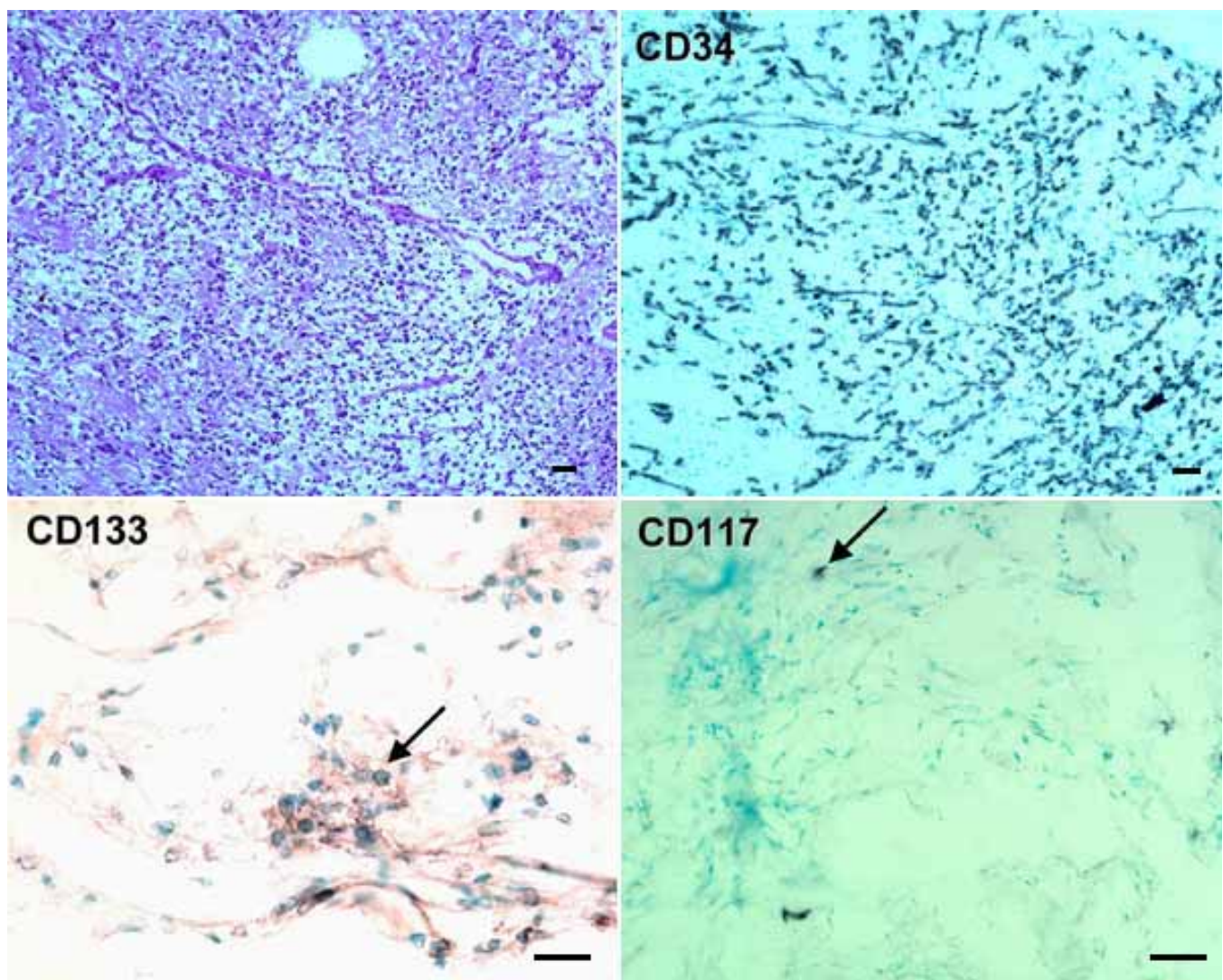


Figure 2. Stem cell markers in a retinal hemangioblastoma. Many positive cells (black bluish color) are stained with CD34 and CD133 (arrow). Only occasional positive CD117 cells (arrow) are seen. The upper left panel was stained with hematoxylin & eosin. The other panels represent avidin-biotin-complex counterstained with methyl green. The original magnifications of the upper and lower panels were 100x and 200x, respectively. The scale bars represent 40 μm .

small clusters admixed in the inner retinal layer (Figure 1B,D). Therefore, we refer to these cells as “tumorlet-like cells.” Also, reactive glial proliferation was observed at some large tumor margins (Figure 2A). Similar observations have been described previously [27].

Detection of stem cell markers in ocular VHL hemangioblastomas: Positive CD31 staining outlined the vascular endothelial cells. CD34 staining was detected mostly along the vascular channel walls (Figure 2B). Although CD31 and CD34 cells overlapped in most areas, CD34 positive cells outnumbered CD31 positive cells. CD133, a transmembrane protein expressed on hematopoietic, endothelial, and neural progenitor cells [28], was positive in all cases. The CD133 positive cells were diffusely or scantily distributed within the individual hemangioblastoma (Figure 2C, Figure 3B,D). Many VHL cells and tumorlet-like cells stained positively; however, the vascular walls were not always positive. Interestingly, CD117,

the c-kit tyrosine kinase receptor and the stem cell factor receptor [29], was sparsely positive or completely negative in some hemangioblastomas (Figure 2D, Figure 3C).

Expression of Epo and EpoR in ocular VHL hemangioblastomas: Epo and EpoR expression was observed in the VHL lesions in six specimens. Among these specimens, the staining of EpoR was more intense and diffuse as compared to Epo in most areas (Figure 4A). Epo and EpoR were expressed mainly in tumorlet-like cells or near “premature” VHL cells. In a few rare instances, Epo and EpoR staining were not located in the same areas. *Epo* and *EpoR* transcripts were detected in microdissected tumor cells (Figure 4B).

DISCUSSION

Ocular hemangioblastomas associated with VHL are composed of tumorlet-like cells that stain positively for stem cell markers. These cells seem to represent “immature” VHL cells.

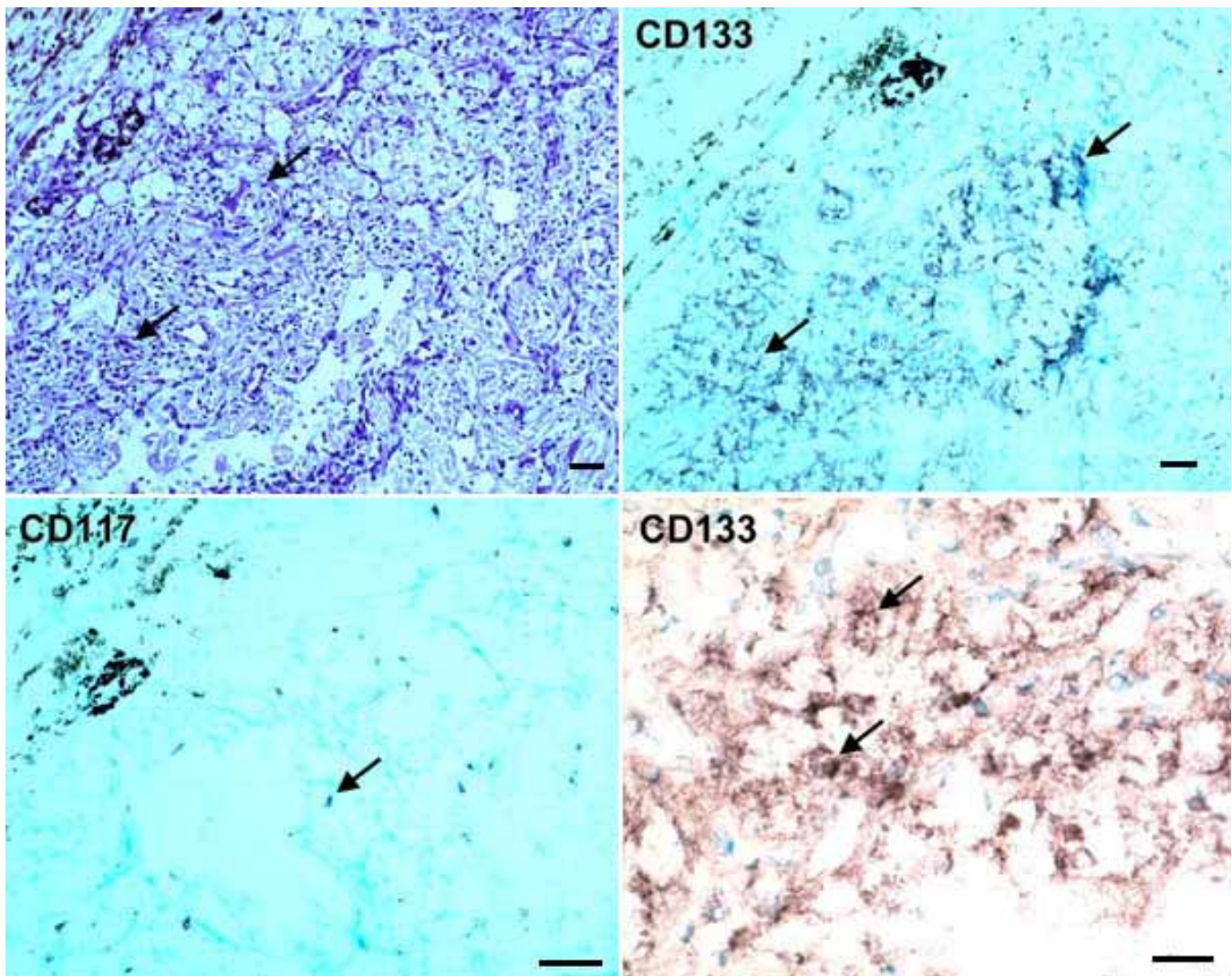


Figure 3. Stem cell markers in another hemangioblastoma. Positive cells (black bluish) for CD133 (arrows) highlight the VHL cells. Only a few positive CD117 cells (arrow) are seen. The upper left panel was stained with hematoxylin & eosin. The other panels represent avidin-biotin-complex counterstained with methyl green. The original magnifications of the upper and lower panels were 200x and 400x, respectively. The scale bars represent 50 μ m.

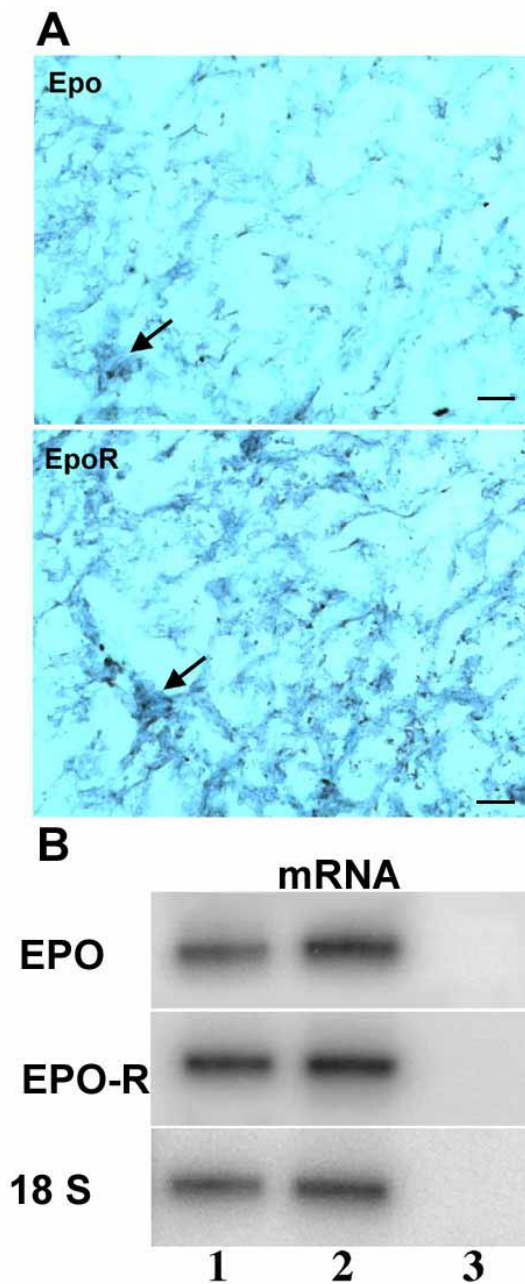


Figure 4. Epo and EpoR in retinal hemangioblastoma. **A:** microphotographs show the expression of Epo- and EpoR-staining cells (black bluish color, arrows) on the VHL lesion. The images labeled epo and epoR were reacted with primary antibodies, respectively, against epo and epoR, secondary biotin-conjugated antibodies, and avidin-biotin-peroxidase complex, and counterstained with methyl green. The original magnification was 200x. The scale bar represents 40 μ m. **B:** Autoradiography showed expression of Epo mRNA and EpoR mRNA from VHL cells in two cases analyzed by RT-PCR (lanes 1 and 2). Lane 3 is a negative control, in which microdissected RNA was omitted. The primer sequences are from [18]. Both RT-PCR primer pairs spanned at least one intron. The expected products for Epo, EpoR, and 18S are 276 bp, 224 bp, and 459 bp, respectively. The RNA from the isolation of the microdissected cells was digested with DNase 1 for several hours. The RT-PCR resulted in a single band of the expected size from an mRNA template. This indicates that there is no genomic DNA contamination, which would create a band of a larger size if intronic sequences were present.

These “immature” cells may be similar to the tumorlets seen in arrested hemangioblastoma [26]. Here, we demonstrated for the first time that ocular VHL lesions express several important stem cell markers. These markers exhibit expression patterns similar to those found in brain tumors such as medulloblastoma and malignant glioma [30,31].

CD133 (AC133 antigen, human prominin 1; OMIM 604365) was first described in 1997 as an antigen to which the AC133 monoclonal antibody binds, and a glycosylated 5-transmembrane protein of unknown function [32]. When discovered, the antigen was thought to be a hematopoietic stem cell-specific marker expressed on various types of leukemia and some lymphoma cells [33-35]. However, CD133 expression was also detected in undifferentiated epithelium, retinoblastomas, teratocarcinomas, hemangioblastomas, and kidney and brain tumors [30,32,36,37]. Furthermore, in addition to hematopoietic stem cells, CD133 has been identified in different stem cells [28,38,39]. Thus, this glycoprotein has become a specific marker for various stem and progenitor cell populations including endothelial, hematopoietic, and neural tissue. Recent studies on a cancer stem cell in human malignant tumors have demonstrated that clonal populations of neoplastic cells exhibit marked heterogeneity with respect to proliferation, self renewal, and differentiation [31,39,40]. This cell-type in the brain represents a minority of the tumor cell population and expresses the cell surface marker CD133 [38]. Expression of CD133 in VHL lesions is consistent with that stem cells are a component of ocular hemangioblastomas.

CD117, the stem cell factor receptor (SCF), is the c-Kit proto-oncogene [29,41]. c-Kit is the cellular homolog of the viral oncogene v-Kit [42]. CD117 is expressed in normal hematopoietic progenitors of the erythroid, granulo-monocytic, and megakaryocytic cells in normal bone marrow. CD117 is present in mast cells, melanocytes, and some carcinoma cell lines as well. Hematopoietic stem cells co-express CD117 and CD133 on their surfaces [43]. Expression of CD117 is highly specific for acute myelogenous leukemia [44]. The lack of CD117 positive cells in our cases suggests that VHL cells may not have myeloid or neural crest lineage.

CD34, a heavily glycosylated Type I transmembrane protein, was first detected in hematopoietic and lymphopoietic progenitors [45,46]. Despite some controversy, CD34 has been used as a conventional stem cell marker for hematopoietic and endothelial cell populations [47,48]. CD34 has been demonstrated in VHL lesions of cerebellar hemangioblastoma and in endolymphatic sac tumors [49-51]. The current study illustrated CD34 positive cells in ocular VHL lesions. These cells seem to closely follow the vascular and Epo/EpoR distribution patterns observed in ocular hemangioblastomas. CD34 positive cells in ocular hemangioblastomas may include the angiogenic precursors that have been well documented in VHL lesions [15,52-54]. Therefore, CD34 stains immature neovascular endothelial cells, which are typically negative for the CD31 marker.

Epo is reported to regulate various human malignancies by its involvement in tumor growth, viability and angiogenesis [55]. In erythropoiesis, Epo prevents apoptosis of Epo-

responsive erythroid precursor cells and stimulates their proliferation and differentiation into erythrocytes. The binding of Epo to EpoR leads to the activation of a transcriptional factor, STAT5, which then induces mitosis of the erythroid precursor cells [56]. Expression of Epo and EpoR has been reported in embryonic stem cells and tumors found in the CNS, uterus, and ovaries [55,57,58]. The signaling pathways of Epo and EpoR are involved in tumorigenesis. Epo contributes to the growth, viability, and angiogenesis of malignant cells and capillary endothelial cells in the tumors by protecting them from apoptosis and stimulating them to proliferate. However, these cells do not regulate the number of EpoR sites as in erythroid differentiation; therefore, Epo appears to cause unlimited proliferation. Co-expression of these two proteins may reflect a developmental arrest in CNS angioblasts and renal immature mesenchymal cells and indicate that progenitor cells are involved in VHL lesions [18,59]. Similar to VHL-associated CNS hemangioblastoma and renal clear cell carcinoma, this study showed expression of Epo and EpoR, particularly EpoR, in ocular hemangioblastomas.

In summary, this study illustrates tumorlet-like cells and CD133, CD34, and Epo/EpoR positive cells in ocular VHL hemangioblastomas. These findings suggest that these cells may represent potentially immature tumor VHL cells within the eye. These tumorlet-like cells require further investigation. Our data may contribute to a better understanding of the tumorigenesis involved in ocular VHL hemangioblastoma and, by suggesting the possible use of CD133/AC133+ stem cell-targeting therapy, may help to identify better strategies in the management of this disease.

ACKNOWLEDGEMENTS

The authors wish to thank Christine Bojanowski for editorial assistance. The study was supported through the Intramural Program of the NEI and NINDS.

REFERENCES

- Linehan WM, Lerman MI, Zbar B. Identification of the von Hippel-Lindau (VHL) gene. Its role in renal cancer. *JAMA* 1995; 273:564-70.
- Lonser RR, Glenn GM, Walther M, Chew EY, Libutti SK, Linehan WM, Oldfield EH. von Hippel-Lindau disease. *Lancet* 2003; 361:2059-67.
- Mahe ER, Webster AR, Moore AT. Clinical features and molecular genetics of Von Hippel-Lindau disease. *Ophthalmic Genet* 1995; 16:79-84.
- Welch RB. Von Hippel-Lindau disease: the recognition and treatment of early angiomas of the retina and the use of cryosurgery as an adjunct to therapy. *Trans Am Ophthalmol Soc* 1970; 68:367-424.
- Richard S, David P, Marsot-Dupuch K, Giraud S, Beroud C, Resche F. Central nervous system hemangioblastomas, endolymphatic sac tumors, and von Hippel-Lindau disease. *Neurosurg Rev* 2000; 23:1-4.
- Wanebo JE, Lonser RR, Glenn GM, Oldfield EH. The natural history of hemangioblastomas of the central nervous system in patients with von Hippel-Lindau disease. *J Neurosurg* 2003; 98:82-94.
- Hammel P, Beigelman C, Chauveau D, Resche F, Bougerolles E, Flejou JF, Bernades P, Delchier JC, Richard S. [Variety of pancreatic lesions observed in von Hippel-Lindau disease. Apropos of 8 cases]. *Gastroenterol Clin Biol* 1995; 19:1011-7.
- Webster AR, Mahe ER, Moore AT. Clinical characteristics of ocular angiomas in von Hippel-Lindau disease and correlation with germline mutation. *Arch Ophthalmol* 1999; 117:371-8.
- Seizinger BR, Rouleau GA, Ozelius LJ, Lane AH, Farmer GE, Lamiell JM, Haines J, Yuen JW, Collins D, Majoor-Krakauer D, Bonner T, Mathew C, Rubenstein A, Halperin J, McConkie-Rosell A, Green JS, Trofatter JA, Ponder BA, Eierman L, Bowme MR, Schimke R, Oostra B, Aronin N, Smith DI, Drabkin H, Waziri MH, Hobbs WJ, Martuza RL, Conneally PM, Hsia YE, Gusella JF. Von Hippel-Lindau disease maps to the region of chromosome 3 associated with renal cell carcinoma. *Nature* 1988; 332:268-9.
- Zbar B, Brauch H, Talmadge C, Linehan M. Loss of alleles of loci on the short arm of chromosome 3 in renal cell carcinoma. *Nature* 1987; 327:721-4.
- Knudson AG Jr. Mutation and cancer: statistical study of retinoblastoma. *Proc Natl Acad Sci U S A* 1971; 68:820-3.
- Knudson AG. Two genetic hits (more or less) to cancer. *Nat Rev Cancer* 2001; 1:157-62.
- Kaelin WG Jr. Molecular basis of the VHL hereditary cancer syndrome. *Nat Rev Cancer* 2002; 2:673-82.
- Hewitson KS, McNeill LA, Schofield CJ. Modulating the hypoxia-inducible factor signaling pathway: applications from cardiovascular disease to cancer. *Curr Pharm Des* 2004; 10:821-33.
- Chan CC, Vortmeyer AO, Chew EY, Green WR, Matteson DM, Shen DF, Linehan WM, Lubensky IA, Zhuang Z. VHL gene deletion and enhanced VEGF gene expression detected in the stromal cells of retinal angioma. *Arch Ophthalmol* 1999; 117:625-30.
- Chan CC, Lee YS, Zhuang Z, Hackett J, Chew EY. Von Hippel-Lindau gene deletion and expression of hypoxia-inducible factor and ubiquitin in optic nerve hemangioma. *Trans Am Ophthalmol Soc* 2004; 102:75-81.
- Wiesener MS, Eckardt KU. Erythropoietin, tumours and the von Hippel-Lindau gene: towards identification of mechanisms and dysfunction of oxygen sensing. *Nephrol Dial Transplant* 2002; 17:356-9.
- Vortmeyer AO, Frank S, Jeong SY, Yuan K, Ikejiri B, Lee YS, Bhowmick D, Lonser RR, Smith R, Rodgers G, Oldfield EH, Zhuang Z. Developmental arrest of angioblastic lineage initiates tumorigenesis in von Hippel-Lindau disease. *Cancer Res* 2003; 63:7051-5.
- Krieg M, Marti HH, Plate KH. Coexpression of erythropoietin and vascular endothelial growth factor in nervous system tumors associated with von Hippel-Lindau tumor suppressor gene loss of function. *Blood* 1998; 92:3388-93.
- Pastore Y, Jedlickova K, Guan Y, Liu E, Fahner J, Hasle H, Prchal JF, Prchal JT. Mutations of von Hippel-Lindau tumor-suppressor gene and congenital polycythemia. *Am J Hum Genet* 2003; 73:412-9. Erratum in: *Am J Hum Genet* 2004; 74:598.
- Pastore YD, Jelinek J, Ang S, Guan Y, Liu E, Jedlickova K, Krishnamurti L, Prchal JT. Mutations in the VHL gene in sporadic apparently congenital polycythemia. *Blood* 2003; 101:1591-5.
- Maran J, Prchal J. Polycythemia and oxygen sensing. *Pathol Biol (Paris)* 2004; 52:280-4.
- Wiesener MS, Seyfarth M, Warnecke C, Jurgensen JS, Rosenberger C, Morgan NV, Mahe ER, Frei U, Eckardt KU. Paraneoplastic erythrocytosis associated with an inactivating

- point mutation of the von Hippel-Lindau gene in a renal cell carcinoma. *Blood* 2002; 99:3562-5.
24. Percy MJ, McMullin MF, Jowitt SN, Potter M, Treacy M, Watson WH, Lappin TR. Chuvash-type congenital polycythemia in 4 families of Asian and Western European ancestry. *Blood* 2003; 102:1097-9.
 25. Ang SO, Chen H, Gordeuk VR, Sergueeva AI, Polyakova LA, Miasnikova GY, Kralovics R, Stockton DW, Prchal JT. Endemic polycythemia in Russia: mutation in the VHL gene. *Blood Cells Mol Dis* 2002; 28:57-62.
 26. Vortmeyer AO, Yuan Q, Lee YS, Zhuang Z, Oldfield EH. Developmental effects of von Hippel-Lindau gene deficiency. *Ann Neurol* 2004; 55:721-8.
 27. Vortmeyer AO, Chan CC, Chew EY, Matteson DM, Shen DF, Wellmann A, Weil R, Zhuang Z. Morphologic and genetic analysis of retinal angioma associated with massive gliosis in a patient with von Hippel-Lindau disease. *Graefes Arch Clin Exp Ophthalmol* 1999; 237:513-7.
 28. Bhatia M. AC133 expression in human stem cells. *Leukemia* 2001; 15:1685-8.
 29. Escribano L, Ocqueteau M, Almeida J, Orfao A, San Miguel JF. Expression of the c-kit (CD117) molecule in normal and malignant hematopoiesis. *Leuk Lymphoma* 1998; 30:459-66.
 30. Hemmati HD, Nakano I, Lazareff JA, Masterman-Smith M, Geschwind DH, Bronner-Fraser M, Kornblum HI. Cancerous stem cells can arise from pediatric brain tumors. *Proc Natl Acad Sci U S A* 2003; 100:15178-83.
 31. Singh SK, Clarke ID, Terasaki M, Bonn VE, Hawkins C, Squire J, Dirks PB. Identification of a cancer stem cell in human brain tumors. *Cancer Res* 2003; 63:5821-8.
 32. Miraglia S, Godfrey W, Yin AH, Atkins K, Warnke R, Holden JT, Bray RA, Waller EK, Buck DW. A novel five-transmembrane hematopoietic stem cell antigen: isolation, characterization, and molecular cloning. *Blood* 1997; 90:5013-21.
 33. Koehl U, Zimmermann S, Esser R, Sorensen J, Gruttner HP, Duchscherer M, Seifried E, Klingebiel T, Schwabe D. Autologous transplantation of CD133 selected hematopoietic progenitor cells in a pediatric patient with relapsed leukemia. *Bone Marrow Transplant* 2002; 29:927-30.
 34. Kratz-Albers K, Zuhlsdorf M, Leo R, Berdel WL, Buchner T, Serve H. Expression of a AC133, a novel stem cell marker, on human leukemic blasts lacking CD34-antigen and on a human CD34+ leukemic line:MUTZ-2. *Blood* 1998; 92:4485-7.
 35. Buhning HJ, Seiffert M, Marxer A, Weiss B, Faul C, Kanz L, Brugger W. AC133 antigen expression is not restricted to acute myeloid leukemia blasts but is also found on acute lymphoid leukemia blasts and on a subset of CD34+ B-cell precursors. *Blood* 1999; 94:832-3.
 36. Kleinman ME, Tepper OM, Capla JM, Bhatt KA, Ceradini DJ, Galiano RD, Blei F, Levine JP, Gurtner GC. Increased circulating AC133+ CD34+ endothelial progenitor cells in children with hemangioma. *Lymphat Res Biol* 2003; 1:301-7.
 37. Florek M, Haase M, Marzesco AM, Freund D, Ehninger G, Huttner WB, Corbeil D. Prominin-1/CD133, a neural and hematopoietic stem cell marker, is expressed in adult human differentiated cells and certain types of kidney cancer. *Cell Tissue Res* 2005; 319:15-26.
 38. Singh SK, Hawkins C, Clarke ID, Squire JA, Bayani J, Hide T, Henkelman RM, Cusimano MD, Dirks PB. Identification of human brain tumour initiating cells. *Nature* 2004; 432:396-401.
 39. Singh SK, Clarke ID, Hide T, Dirks PB. Cancer stem cells in nervous system tumors. *Oncogene* 2004; 23:7267-73.
 40. Dick JE. Breast cancer stem cells revealed. *Proc Natl Acad Sci U S A* 2003; 100:3547-9.
 41. Lev S, Blechman JM, Givol D, Yarden Y. Steel factor and c-kit protooncogene: genetic lessons in signal transduction. *Crit Rev Oncog* 1994; 5:141-68.
 42. Ronnstrand L. Signal transduction via the stem cell factor receptor/c-Kit. *Cell Mol Life Sci* 2004; 61:2535-48.
 43. Ruzicka K, Grskovic B, Pavlovic V, Qujeq D, Karimi A, Mueller MM. Differentiation of human umbilical cord blood CD133+ stem cells towards myelo-monocytic lineage. *Clin Chim Acta* 2004; 343:85-92.
 44. Baersch G, Baumann M, Ritter J, Jurgens H, Vormoor J. Expression of AC133 and CD117 on candidate normal stem cell populations in childhood B-cell precursor acute lymphoblastic leukaemia. *Br J Haematol* 1999; 107:572-80.
 45. Silvestri F, Banavali S, Baccarani M, Preisler HD. The CD34 hemopoietic progenitor cell associated antigen: biology and clinical applications. *Haematologica* 1992; 77:265-73.
 46. Krause DS, Fackler MJ, Civin CI, May WS. CD34: structure, biology, and clinical utility. *Blood* 1996; 87:1-13.
 47. Guo Y, Lubbert M, Engelhardt M. CD34- hematopoietic stem cells: current concepts and controversies. *Stem Cells* 2003; 21:15-20.
 48. Schatteman GC, Awad O. In vivo and in vitro properties of CD34+ and CD14+ endothelial cell precursors. *Adv Exp Med Biol* 2003; 522:9-16.
 49. Miettinen M, Lindenmayer AE, Chaubal A. Endothelial cell markers CD31, CD34, and BNH9 antibody to H- and Y-antigens—evaluation of their specificity and sensitivity in the diagnosis of vascular tumors and comparison with von Willebrand factor. *Mod Pathol* 1994; 7:82-90.
 50. Vaquero J, Zurita M, Coca S, Salas C, Oya S. Expression of vascular endothelial growth factor in cerebellar hemangioblastomas does not correlate with tumor angiogenesis. *Cancer Lett* 1998; 132:213-7.
 51. Horiguchi H, Sano T, Toi H, Kageji T, Hirokawa M, Nagahiro S. Endolymphatic sac tumor associated with a von Hippel-Lindau disease patient: an immunohistochemical study. *Mod Pathol* 2001; 14:727-32.
 52. Aiello LP, George DJ, Cahill MT, Wong JS, Cavallerano J, Hannah AL, Kaelin WG Jr. Rapid and durable recovery of visual function in a patient with von hippel-lindau syndrome after systemic therapy with vascular endothelial growth factor receptor inhibitor su5416. *Ophthalmology* 2002; 109:1745-51.
 53. Girmens JF, Erginay A, Massin P, Scigalla P, Gaudric A, Richard S. Treatment of von Hippel-Lindau retinal hemangioblastoma by the vascular endothelial growth factor receptor inhibitor SU5416 is more effective for associated macular edema than for hemangioblastomas. *Am J Ophthalmol* 2003; 136:194-6.
 54. Akiyama H, Tanaka T, Itakura H, Kanai H, Maeno T, Doi H, Yamazaki M, Takahashi K, Kimura Y, Kishi S, Kurabayashi M. Inhibition of ocular angiogenesis by an adenovirus carrying the human von Hippel-Lindau tumor-suppressor gene in vivo. *Invest Ophthalmol Vis Sci* 2004; 45:1289-96.
 55. Yasuda Y, Fujita Y, Matsuo T, Koinuma S, Hara S, Tazaki A, Onozaki M, Hashimoto M, Musha T, Ogawa K, Fujita H, Nakamura Y, Shiozaki H, Utsumi H. Erythropoietin regulates tumour growth of human malignancies. *Carcinogenesis* 2003; 24:1021-9. Erratum in: *Carcinogenesis* 2003; 24:1567.
 56. Youssoufian H, Longmore G, Neumann D, Yoshimura A, Lodish HF. Structure, function, and activation of the erythropoietin receptor. *Blood* 1993; 81:2223-36.

57. Acs G, Zhang PJ, Rebbeck TR, Acs P, Verma A. Immunohistochemical expression of erythropoietin and erythropoietin receptor in breast carcinoma. *Cancer* 2002; 95:969-81.
58. Acs G, Xu X, Chu C, Acs P, Verma A. Prognostic significance of erythropoietin expression in human endometrial carcinoma. *Cancer* 2004; 100:2376-86.
59. Lee YS, Vortmeyer AO, Lubensky IA, Vogel TW, Ikejiri B, Ferlicot S, Benoit G, Giraud S, Oldfield EH, Linehan WM, Teh BT, Richard S, Zhuang Z. Coexpression of erythropoietin and erythropoietin receptor in von Hippel-Lindau disease-associated renal cysts and renal cell carcinoma. *Clin Cancer Res* 2005; 11:1059-64.